

*Original Research***Gross Studies on Penis of the Boar (*Sus scrofa domesticus*)****E. Raja Ravi Teja*, N. Rajendranath, G. Purushotham and M. Lakshman**Department of Veterinary Anatomy, College of Veterinary Science, PVNRTVU, Rajendranagar
– 500030, Telangana, INDIA*Corresponding author: ersavadlar@gmail.com

| | |
|--------------|---|
| Rec. Date: | Jun 02, 2017 17:40 |
| Accept Date: | Oct 21, 2017 17:16 |
| DOI | 10.5455/ijlr.20170602054025 |

Abstract

Gross studies were conducted on penises of six adult boars. Gross anatomical features revealed that penis of boar was cylindrical in shape with a root, body and tip which extended up to umbilicus. Body of the penis formed an 'S' shaped sigmoid flexure anterior to the scrotum. Root of boar penis comprised two crura and a bulbous urethrae. Mean length, width and diameter of penis was 32.17 ± 0.49 cm, 0.63 ± 0.04 cm and 2.37 ± 0.06 cm respectively.

Key words: Body, Gross, Root, Tip

How to cite: Ersavadla, R., Nalla, R., Gudepu, P., & Mekala, L. (2019). Gross Studies on Penis of The Boar (*Sus scrofa domesticus*). International Journal of Livestock Research, 9(7), 242-245. doi: 10.5455/ijlr.20170602054025

Introduction

The penis of boar resembles that of the ox penis in general. The 'S' shaped sigmoid flexure is prescrotal. It contains much connective tissue being intermediate between the engorging type of most mammals and the fibro-elastic type of ruminants. The anterior part spirally twisted especially in erection. The external urethral orifice is slit-like and situated ventro laterally close to pointed extremity. The penis formed by two crura and penile urethra ventral to the crura. The penis was corkscrew shaped and occupied the space between the thighs and presented a prescrotal sigmoid flexure Sisson and Grossman (1975), Nickel, Schummer and Seiferle (1979) in boar, Ziehmer *et al.* (2013) in Babirusa pig. The penis was divisible into a root, body and glans in bull Macleod (1958); Warwick and Williams (1973). The body of the penis began at the junction of the two crura and forms the major part of the organ Sisson and Grossman (1975); Nickel, Schummer and Seiferle (1979) in pig; Hafez and Hafez (2000) in bull; Ziehmer *et al.* (2013) in Babirusa. The proximal curve of the sigmoid flexure opened caudally and distal curve opened cranially, the penis was round in the middle and flat at the tip. The free part of the penis was tapering and twisted spirally. The external urethral

orifice was slit-like and situated ventro-laterally close to the pointed free part of the penis in pig Nickel, Schummer and Seiferle (1979), in Babirusa pig Ziehmer *et al.* (2013).

The prepuce was longer than the free part of the penis and covered the tip in non-erected condition. The preputial orifice formed by a thick annular fold of skin covered with a tuft of stiff hairs. The dorsal wall of the prepuce was wide with a preputial diverticulum containing a foul-smelling fluid made of cell debris soaked with urine in common large breed pig Nickel, Schummer and Seiferle (1979). The length of penis was 29.2 cm in Piétrain german Willeke (1992) and 29.9 cm in adult indigenous boars Akingbemi and Makinde (1995). The average length, width and thickness of free part of the penis were as 4.0 cm, 0.60 cm and 0.30 cm respectively in common large breed pigs Nickel and Schummer (1979).

Material and Methods

Samples for this study were collected from six apparently healthy adult male pigs. The adnexa of penis gently dissected and photographed accordingly. Morphometrical observations of penis like length and width at the root, body and glans penis were recorded afresh by digital vernier calipers, thread and scale technique.

Results and Discussion

In the present study the penis of the boar was cylindrical in shape and consisted of a root, body and tip (Fig.1). It occupied the space between the thighs and extended from the ischial arch to the umbilicus passing anteriorly through the inguinal area subcutaneously on the ventro-median line of the abdomen. Similar observations were made by several authors such as Sisson and Grossman (1975); Nickel Schummer and Seiferle (1979) in pigs; Babinski (2004) in wild boars and Ziehmer *et al.* (2013) in Babirusa pigs.

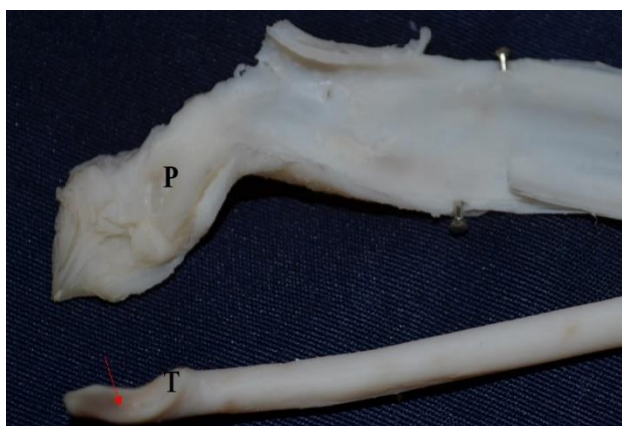


Fig. 1: Photograph showing penis of boar. C - Crura, U - Urethra, R - Root, RPM - Retractor penis muscle, SF- Sigmoid flexure, T -Tip of the penis, P - Prepuce.

Root of boar penis comprised two crura and a ventrally placed bulbous urethrae (Fig. 2). These observations are in total agreement with the findings of Warwick and Williams (1973) in bulls. The body formed the

major part of the penis in boar and was round in the middle and flat at the tip. It formed a 'S' shaped sigmoid flexure anterior to the scrotum in the inguinal region (Fig. 1).



Fig. 2: Photograph showing root of the boar penis. Cr – Crura and Bulbous urethra (BU).

These observations were almost similar to the findings of several authors like Macleod (1958); Warwick and Williams (1973) and Hafez and Hafez (2000) in bulls; Sisson and Grossman (1975); Nickel and Schummer (1979) in pigs and Ziehmer *et al.* (2013) in Babirusa pigs. Retractor penis muscles originated from the third sacral vertebra and inserted to the body of penis in front of the sigmoid flexure (Fig.1) which is similar to the description of penis of pig by Reece (2010) and in pigs and bulls by Sisson and Grossman (1975) and Dyce *et al.* (2010). Tip of the penis was spirally curved and was covered by the prepuce (Fig. 3). The external urethral orifice was small slit like and situated ventro-laterally on the tip of the penis. The prepuce consisted external and internal layer. Internal layer covered the tip and anterior one third of the body of boar penis (Fig. 3).

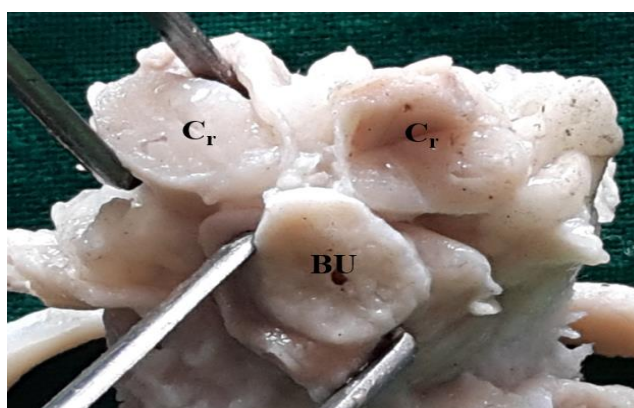


Fig. 3: Photograph showing penis and prepuce in boar. T - Tip of the penis and P - Internal layer of preputial sheath

Morphometrical observations of boar penis revealed the average length, width and the diameter of the penis was 32.17 ± 0.49 cm, 0.63 ± 0.04 cm and 2.37 ± 0.06 cm respectively. These measurements are in partial

agreement with the Trotter (1959) who recorded the length and average diameter of penis as 36-40 inches and 1 to 1^{1/2} inches respectively in bulls and 45-50 cm in boars Sisson and Grossman (1975). Length of penis was 29.2, 30.6 and 29.9 cm in Piétraingerman pigs Willeke (1992), Belgian landrace boars and in adult indigenous boars Akingbemi and Makinde (1995). In the present study the average length and width of the body of the penis was recorded as 26 ± 0.45 cm and 0.8 ± 0.03 cm. Average length and width of the tip of boar penis was 2.37 ± 0.04 cm and 0.41 ± 0.03 cm respectively in the present study which is in partial agreement with findings of Sisson and Grossman (1975), Nickel, Schummer and Seiferle (1979) in the free part of the penis of common large breed pigs.

Conclusion

The sigmoid flexure in boar penis is prescrotal in position. The morphometrical studies reveals that the diameter of the penis reducing from the body towards the tip.

Acknowledgement

The authors are very thankful to the P.V Narsimha Rao Telangana Veterinary University to carry out the present work.

References

1. Akingbemi BT and Makinde MO. 1995. Evaluation of some reproductive parameters in the indigenous boar of Zimbabwe. *Onderstepoort Journal of Veterinary Research*. 62 (1): 59-61.
2. Dyce KM, Sack WO and Wensing CJG. 2010. Text book of veterinary anatomy. 4th edn. Saunders – Elsevier, St. Louis, Missouri. pp. 777-778.
3. Hafez B and Hafez ESE. 2000. Reproduction in farm animals. 7th edn. Lippincott Williams & Wilkins, Baltimore, Maryland, USA. pp. 3 & 10.
4. Macleod WM. 1958. Bovine anatomy, Burgess Publishing Company, Minnesota.
5. Nickel R, Schummer A and Seiferle E. 1979. The Viscera of the Domestic Mammals. 2nd revised edn. Verlag Paul Parey, Berlin.
6. Reece WO. 2010. Functional anatomy and physiology of domestic animals. 4th edn. Jhon Wiley & Sons.
7. Sisson S and Grossman JD. 1975. Anatomy of domestic animals. 5th edition. W.B. Saunders, Philadelphia U.S.A. pp.601.
8. Trotter DM. 1959. Histological observations of the genitalia of the immature, the castrated and the mature bovine males. *American Journal of Veterinary Research*. 20: 213.
9. Warwick R and Williams PL. 1973. Gray's anatomy. Longman Group Ltd, London.
10. Willeke H. 1992. Penis length of boars: breed differences and repeatability of measurements. *Aurchiv fur tierzucht*. 35(1-2): 137-141.
11. Ziehmer B, Ogle S, Signorella A, Knorr C and Macdonald AA. 2013. The anatomy and histology of the reproductive tract of the male Babirusa (*Babirusa celebensis*). *Theriogenology*. 79(7): 1054-1064.