



# A Rare Case of Haematic Fetal Mummification in An American Bully Dog

Pururava Sharma<sup>1</sup>, Pravesh Kumar<sup>1\*</sup>, Akshay Sharma<sup>1</sup>, Vijender Negi<sup>1</sup>, Harish Kumar<sup>1</sup>, Pankaj Sood<sup>1</sup> and Anurag Sharma<sup>2</sup>

<sup>1</sup>Department of Veterinary Gynaecology and Obstetrics, College of Veterinary and Animal Sciences, CSKHPKV, Palampur- 176062, INDIA

<sup>2</sup>Department of Animal Genetics and Breeding, College of Veterinary and Animal Sciences, CSKHPKV, Palampur- 176062, INDIA

\*Corresponding Author: [pk9919@gmail.com](mailto:pk9919@gmail.com)

## How to cite this paper:

Sharma, P., Kumar, P., Sharma, A., Negi, vijender, Kumar, H., Sood, P., & Sharma, A. (2022). A Rare Case of Haematic Fetal Mummification in An American Bully Dog. *International Journal of Livestock Research*, 12(12), 23-26.

**Received** : Sep 03, 2022

**Accepted** : Dec 27, 2022

**Published** : Dec 31, 2022

Copyright © Sharma *et al.*, 2022

This work is licensed under the Creative Commons Attribution International License (CC BY 4.0).  
<http://creativecommons.org/licenses/by/4.0/>



## Abstract

*Fetal mummification is defined as the resorption of fetal fluid within the uterus as the cervix remains closed due to the presence of the corpus luteum on the ovary. It is seen in late gestation only after the ossification of fetal bones. The present case was reported in an American bully female dog where three mummified pups were removed out of which two were mummified dead fetuses and one was live through cesarean section. The she-dog recovered following post-operative management.*

**Keywords:** American Bully Dog, Fetal Mummification

## Introduction

Several sequelae of fetal death in uterus have been seen in animals which include mummification, maceration and partial or complete abortion (Verma *et al.*, 2021). Mummification in fetus is an uncommon condition in most of the domestic animals. In fetal mummification, the fetus dies and the fetal fluid is absorbed, causing the uterus to contract and the fetal membranes to stick to the fetus (Kumar *et al.*, 2010; Noakes *et al.*, 2019). It occurs when a fetus dies after the first trimester of pregnancy and has completely grown skin that is resistant to autolysis (Bindari and Shrestha, 2012; Ahuja *et al.*, 2017). Death of the fetus along with the presence of corpus luteum on the ovary may result in resorption of fetal and placental fluids causing dehydration of fetus and if fetus and fetal contents are retained in the uterus then it results in fetal mummification (Noakes *et al.*, 2019). In monotocous species like cows, it is very common. It is one of the outcomes of fetal death, and it occurs when fetus is retained for a long period (Lefebvre, 2015). Generally, it is of two types depending on presence of exudates. If it is dry having no exudates with stiff fetoplacental unit, it is known as papyraceous mummification and can be seen in dogs, cats, cattle and buffaloes. In other type, a viscous adhesive material covers the mummified fetus is known as hematic or chocolate mummification (Sandoval-Castillo and Villavicencio-Garayzar, 2008).

Fetal mummification is commonly seen in polytocous species like pigs (Kennedy and Miller, 2007) but it is very rare in other polytocous species like dogs (Roberts, 2004; Bindari and Shrestha, 2012; Reis *et al.*, 2017). However, canine mummification is almost similar to swine fetal mummification where mummified fetuses do not impede the survival of other pups which results in the expulsion of one to three fetuses with other normal pups at the time of parturition (Roberts, 2004; Noakes *et al.*, 2019). The major cause of fetal mummification in the dog is the Canine herpes virus and other infectious agents (Canine parvovirus type 1, *Toxoplasma*) or non-infectious causes of fetal loss, such as hypothyroidism and chromosome abnormalities, may potentially cause fetal loss, however, their link to fetal mummification is unclear (Lefebvre, 2015). As fetal mummification is a sterile condition it will not affect the future fertility of the dog.

## Case History

A primiparous American bully aged 2 years with a normal history of delivery of 6 pups in previous whelping was presented at the Department of Veterinary Gynaecology and Obstetrics, Palampur after 64 days of mating. The mating was carried out twice on alternate days after the 9<sup>th</sup> day of cessation of proestrus bleeding. The animal was restless along with signs of inappetence, panting, and straining for the last 6 hours.

The case was presented at the department for pregnancy diagnosis and fetal count fifteen days earlier. The X-ray and colour Doppler ultrasonography of the female dog was done. With X-ray only 3 fetal skeletal along with heads were visible. In ultrasonography, all the fetuses were viable with a normal heartbeat. Mummified fetuses were not visible with the X-ray and colour Doppler ultrasonography.

After a 64-day post-mating, the animal was presented with oozing blackish-green discharge from last night. Per-vagina examination revealed a fully dilated cervix with no fetus in the pelvic cavity. Physical examination showed a pale-colored conjunctival mucus membrane with normal all vital parameters. Hematological examination revealed normocytic-normochromic anemia with 10 gm % haemoglobin along with normal leucocytes and platelets counts. The abdominal X-ray examination showed three fetuses. The ultrasonographic examination was carried out to check the viability of the fetus but the fetuses which were within reach of the ultrasound probe did not show a heartbeat. As the cervix was fully dilated the animal was injected with oxytocin 10 I.U intravenous and calcium Sandoz® (Novartis India) 15 ml intravenous (@ dose rate of 50 mg per kg body weight) diluted in 300 ml of dextrose normal saline to induce uterine contraction for the expulsion of fetuses. She-dog did not show any improvement till one-hour post-treatment and thereby cesarean section was advised.

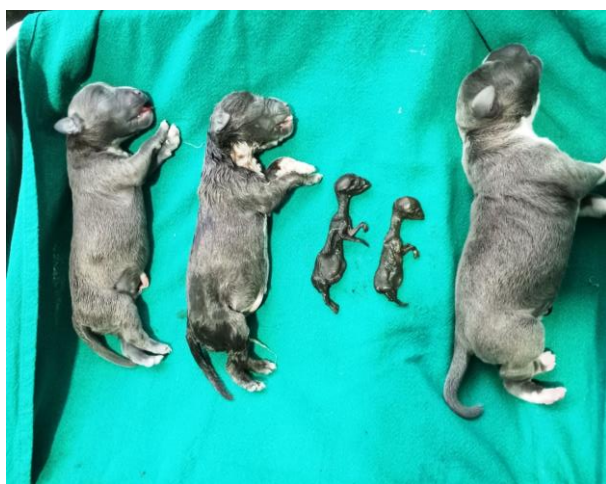## Treatment

The female dog was pre-operatively treated with 562.5 mg of ceftriaxone and tazobactam (Intacef-Tazo®; Intas Pharmaceuticals) @ 15 mg/kg body weight was given intravenously. Opioid analgesic Butorphenol (Butrum®; Ari-Aristo Pharmaceuticals) was given @ 0.2 mg/kg intramuscularly followed by a pre-anesthetic dose of atropine (Tropine®; Neon Laboratories Ltd.) @ 0.02 mg/kg subcutaneously after 10 minutes. After 15 minutes of atropine injection, diazepam (Calmpose®; Ranbaxy Laboratories) @ 0.5mg/kg was given intravenously. The induction of

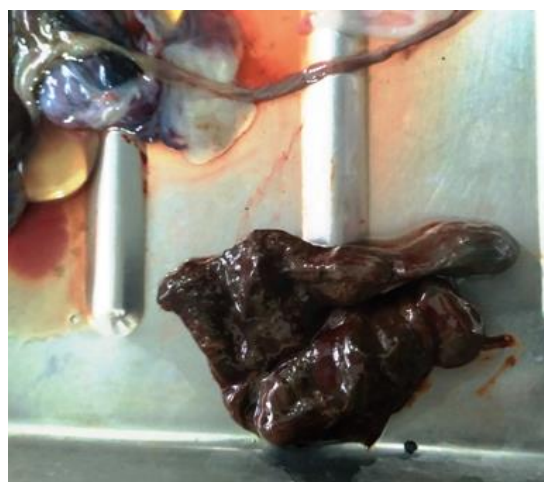
anesthesia was done by propofol (Neorof®; Neon Laboratories Ltd.) @ 3mg/kg body weight by intravenous route. The animal was kept on inhalant anesthetic isoflurane 3 % during the procedure. The status of anesthesia was checked by assessment of pupil dilatation, eyeball position, muscular tonus of mandible, response to surgery pain, and monitoring of other physiological parameters. Physiological parameters like heart rate and respiration rate were monitored from time to time.

The uterus was approached with a mid-ventral incision just behind the umbilicus. The fetuses were stuck at the uterine bifurcation. On the dorsal side of the uterine horn, an incision was made and fetuses were removed. A total of 6 fetuses were removed, out of which one was alive, two were dead with normal size, and three were mummified (Fig 1). In Fig. 1 only two mummified fetuses are visible and 3<sup>rd</sup> mummified fetus was collected later on in placental debris. After the removal of fetuses, the uterus and muscles were sutured using the Cushing pattern and Lockstitch pattern respectively with 2-0 Polyglactin 910 (Vicryl®; Ethicon).

The skin was sutured with silk suture using a simple interrupted pattern. In perioperative time the female dog was given isotonic fluid normal saline (NS®; Beybee Pharmacy) @ 40 ml/kg body weight, and antibiotic therapy was done with ceftriaxone and tazobactam (Intacef-Tazo®; Intas Pharmaceuticals) @ 15 mg/kg body weight at a gap of 12 hours, injection meloxicam @ 0.2 mg/kg body weight once in a day. Antiseptic dressing of the surgical wound was done with povidone-iodine (Betadine®; Win-Medicare Pvt. Ltd.) solution daily till the removal of sutures were removed after 14 days of the surgery.



**Fig. 1:** Mummified fetuses with normal fetuses



**Fig. 2:** Hematic Mummified fetus

## Result and Discussion

Fetal death can occur at any stage of pregnancy, culminating in resorption, abortion, or retention of the fetus, which can become mummified or lead to maceration or pyometra if bacterial contamination occurs (Mudasir *et al.*, 2012). In the present case, six fetuses were delivered out of which three were mummified, two were dead and one was found alive. This implies that the mummification of the fetus does not impart any detrimental effect on the other viable fetuses. The mummified fetuses were surrounded by red gummy tenacious material indicating haematic fetal mummification (Fig. 2). The placental fluids are absorbed, and the fetal membranes stick to the desiccated fetus, forming a black tissue with a moist surface that is free of odours and secretions (Kennedy and Miller 2007). The present case showed haematic fetal mummification in three pups with the delivery of three normal-sized pups. Out of three pups, two were dead which might have died due to a delay in the delivery process at the owner's end.

## Contribution by authors

All the authors contributed equally to writing the manuscript. The final manuscript was read by all others and consented to publication.

## Conflict of Interests

There is no conflict of interest.

## Publisher Disclaimer

IJLR remains neutral concerning jurisdictional claims in published institutional affiliation.

## References

1. Ahuja, A.K., Singh, A.K., Kumar N., and Muddrangiah. (2017). Mummified fetus and Two live fetuses in Labrador Bitch. A Special Case. *International Journal of Current Microbiology and Applied Sciences*, 6(7), 1642-1644.
2. Bindari, Y.R. and Shrestha, S. (2012). Canine fetal mummification. *International Journal of Veterinary Science*, 1(1), 10-12.
3. Kennedy, P.C. and Miller, R.B. (2007). The female genital system. In Kennedy KVF, Palmer PC (Editors). *Pathology of Domestic Animals*. San Diego: Academic Press 4: 349-454.
4. Kumar. P., Vasishta, N., Sharma, A., Singh, M.M. and Barman, P. (2010). Treatment of bovine foetal mummification with Diethyl Stilbesterol (DES). *Indian Journal of Field Veterinarians*, 6(2), 39-40.
5. Lefebvre, R. (2015). Fetal mummification in the major domestic species: current perspectives on causes and management. *Veterinary Medicine: Research and Reports* 6, 233-244.
6. Mudasir, Q., Shah, K.A., Nyrah, Q. and Andrabi, A. (2012). Fetal Mummification in Bitch. *Vet Scan*, 7(1), 97-99.
7. Noakes, D.E., Parkinson, T.J. and England, G.C.W. (2019). Vaginal wall and cervix through the vulva. In: *Veterinary reproduction and obstetrics*. 10<sup>th</sup> Edn Elsevier Company Ltd. London pp: 294.
8. Reis, M.O., Bobany, D.M., Muniz, I.M., Silva, M.E.M. and Luz, M.S. (2017). Fetal hematic mummification in a bitch: case report. *IOSR Journal of Agriculture and Veterinary Sciences*, 10(5), 22-24.
9. Roberts SJ. (2004). *Veterinary Obstetric and Genital Disease*. 2nd edition. CBS Publishers and Distributors, India.
10. Sandoval-Castillo J and Villavicencio-Garayzar C. (2008). Fetal mummification in silky shark (*Carcharhinus falciformis*) from the Gulf of California, Mexico. *Brazilian Archives of Biology and Technology* 51, 551–554.
11. Verma, A.K., Tripathi, A., Patel, A., Singh, A.K., Shukla, M.K. and Singh, V. (2021). An unusual case of fetal maceration in a she dog. *The Haryana Veterinarians* 60(SI), 106-107.

\*\*\*\*\*