



*Original Research*

## Effect of *Emblica officinalis* (Amla) Fruit Powder on Morphometry of the Intestinal Mucosa in Broiler Chicken

Rajesh Dalal\*, Parveen Kumar Ahlawat, Sonu, Nancy Sheoran, V. S. Panwar and B. S. Tewatia

Department of Animal Nutrition, Lala Lajpat Rai University of Veterinary and Animal Sciences, Hisar-125004, Haryana, INDIA

\*Corresponding author: [rajeshdalal.rd@gmail.com](mailto:rajeshdalal.rd@gmail.com)

Rec. Date:	Mar 26, 2018 04:36
Accept Date:	Jun 16, 2018 16:39
DOI	<a href="https://doi.org/10.5455/ijlr.20180326043600">10.5455/ijlr.20180326043600</a>

### Abstract

A total of 300 day old commercial broiler chicks were randomly distributed into six treatments having five replicates consisting of ten birds each. The chicks fed with standard basal diet in two different growth phases i.e. starter (0-28d) and finisher (29-42 d). The first group was kept as control ( $T_1$ ) and given basal diet without antibiotic, while second group ( $T_2$ ) was given basal diet with antibiotic. In third ( $T_3$ ), fourth ( $T_4$ ), fifth ( $T_5$ ) and sixth ( $T_6$ ) groups, basal diet was supplemented with amla fruit powder @ 0.25%, 0.50%, 0.75% and 1%, respectively. Then one bird from each replicate was slaughtered and ileal sample were collected for morphometric analysis. Mean villus height of the birds under different dietary treatments ranged from 984.56  $\mu\text{m}$  to 1196.72  $\mu\text{m}$ . Dietary supplementation of amla fruit powder increased the villi height and significant increment was observed in  $T_6$  followed by  $T_5$  and  $T_4$ . Height: Depth of intestinal crypts of the birds under different dietary treatments ranged from 5.44 to 8.12 and significant effect on the ratio of height: depth of intestinal crypts was recorded in the 0.75% amla powder supplemented group ( $T_5$ ). The morphometric analysis results in the present study showed that the supplementation of antioxidants increased villus height but decreased crypt depth in broilers.

**Key words:** Amla, Intestinal Crypts, Morphometry, Villus

**How to cite:** Dalal, R., Ahlawat, P., Dahiya, S., Sheoran, N., Panwar, V., & Tewatia, B. (2018). Effect of *Emblica officinalis*(amla) Fruit Powder on Morphometry of the Intestinal Mucosa in Broiler Chicken. International Journal of Livestock Research, 8(11), 182-189. doi: 10.5455/ijlr.20180326043600

### Introduction

Poultry industry in India has emerged as one of the fastest growing segment of the agriculture sector, ranking 6<sup>th</sup> in broiler production with an annual output of 2.39 million tonnes of broiler meat (Anonymous, 2015). It is projected that during the period 2000-2020, total poultry meat consumption is likely to expand from 687 million kilograms to 1,674 million kilograms (Mohanty and Rajendran, 2003). The production of safer poultry products without any chemical and microbial residues is the order of the day. Over a period



of time, extensive efforts have been made to lower down the cost of production by lowering the expenses on feed. Feed additives are one of the important tools used for improving feed conversion ratio, growth rate and disease resistance. The range of feed additives used in animal production industry is very broad ranging from growth promoters to disease preventing agents. The mechanism by which the majority of herbal feed additives exert their antibacterial effect is by acting on the bacterial cell wall structure, denaturing and coagulating proteins. Herbal feed additives effects include improving nutrient utilization and stimulation of the immune system. The possible mechanisms of action of herb in the animal for growth promotion include changes in the intestinal microbiota, increased digestibility, nutrient absorption, enhanced nitrogen absorption, improvement of the immune response, morphological and histological modifications of the gastrointestinal tract and antioxidant activity. Herbs can also contribute by stimulating the endocrine system and intermediate nutrient metabolism.

### **Ethical Approval**

The animal experiment was conducted in accordance with guidelines approved by the Institutional Animal Ethics Committee, 12/CPCSEA Dated 6.2.2017 in the Department of Animal Nutrition, Lala Lajpat Rai University of Veterinary and Animal Sciences, Hisar.

### **Experimental Design**

Completely Randomized Design (CRD) was used as experimental design at uniform and standard management practices.

### **Materials and Methods**

A total of 300 commercial broiler chicks (Ven Cobb strain) were randomly distributed into six treatments having five replicates consisting of ten birds each. The chicks fed with standard basal diet in two different growth phase i.e. starter (0-28d) and finisher (29-42d). The first group was kept as control (T<sub>1</sub>) and given the basal diet without antibiotic, while in second group (T<sub>2</sub>) basal diet was given with antibiotic. The diet in third (T<sub>3</sub>), fourth (T<sub>4</sub>), fifth (T<sub>5</sub>) and sixth (T<sub>6</sub>) groups were supplemented with amla fruit powder @ 0.25%, 0.50%, 0.75% and 1%, respectively. Birds were vaccinated against F1 strain of Ranikhet disease on 3<sup>rd</sup> day and IBD on 14<sup>th</sup> day. The birds were weighed fortnightly to calculate growth performance parameters *viz.* feed intake, body weight gain and FCR. Then, one bird from each replicate was slaughtered and ileal samples were collected for intestinal morphological examinations, cross-sections measuring 1 mm to 2 mm thick from ileum were prepared and enclosed in tissue cassettes. The tissues were fixed in 10% neutral buffered formalin over 24 h for each intestinal segment, a 5µm section was placed onto a glass slide and stained with alcian blue and hematoxylin-eosin. Slides were viewed under Fluorescent microscope and visual measurements were taken of the villous length (µm distance from apex of villus to the junction of

the villous and crypt), villous width and crypt depth ( $\mu\text{m}$  distance from the junction to the basement membrane of the epithelial cell at the bottom of the crypt). Feed ingredients used for ration formulations were evaluated for proximate nutrients (AOAC, 2013).

### Figuring and Composition of Diets

Basal ration was formulated as per BIS (2007) to fulfill the metabolizable energy (ME) and crude protein requirements of birds. Level of crude protein in starter (0-4weeks) and finisher (4-6weeks) ration was 22 percent and 20 percent, respectively. The respective ME content was 3000 and 3200 KCal/kg. All feed ingredients, additives and supplements used in the experiment were procured in one lot before the start of the experiment. The ingredients, additives and supplements used in the diet formulation were maize, soybean meal, vegetable oil, fish meal, mineral mixture, vitamins, coccidiostat, lysine, DL- methionine and amla fruit powder. The sources, composition and mixing rate of additives/supplements used in ration formulations are presented in Table 1.

**Table 1:** Ingredient composition of experimental diets during different phases of growth

Ingredient (kg /100 kg of feed)	0-4wks	4-6 wks
Maize	58	60
Soybean meal	30	25
Fish meal	7	7
Vegetable oil	3	6
Mineral mixture	2	2
Feed addivites (g/100 kg feed)		
Spectromix	10	10
Spectromix BE	20	20
Veldot	50	50
Choline chloride	50	50
Lysine	50	50
DL-methionine	150	150

The experimental chicks were reared under deep litter system. The floor of the pens was thoroughly cleaned, disinfected before scattering of the bedding material. Well chopped dry wheat straw was used as bedding material to form the litter. The straw was evenly spread upto 5 cm thickness. The litter was regularly raked to avoid any lump formation. Wooden brooders fitted with bulb in the centre were used in each pen for brooding. The feeding programme consisted of a starter diet until 28 days and a finisher diet from 29 to 42 days of age. Weighed amount of feed was offered on paper sheets for first 3 days and thereafter, in the automatic feeders up to 28 days of age. Afterwards, the feeds were offered through hanging feeders maintained at appropriate heights. The chicks were provided *ad libitum* clean drinking water through the plastic waterers during first two weeks of the experiment. Thereafter, bigger plastic waterers were used till the end of the experiment. Individual body weight of chicks was recorded at 0 day of age and thereafter

fortnightly. At the end of the experiment, one bird from each replicate was slaughtered ethically by mechanical stunning followed by exsanguinates.

### Composition, Sources and Rate of Mixing of Feed Additives/Supplements

1. Spectromix: Powder (Ranbaxy Animal Health, New Delhi). Each gm. contained VitaminA-82,500 IU, Vit D3-12000 IU, Vit B2-50 mg and Vit.K-10mg. Mixing rate: 10 g/100Kg of feed.
2. SpectromixBE: Powder (Ranbaxy Animal Health, New Delhi). Each gm. Contained Vit.B1- 8mg, Vit.B6- 16mg, Vit.B12- 80mg, niacin-120mg, calcium pantothenate-80mg, Vit. E-160 mg, Lysine hydrochloride-10 mg, DL-methionine-10 mg and calcium 260 mg. Mixing rate: 20g/100kg of feed.
3. Veldot: Venkeys- Dinitro-O-Toluamide (Coccidiostat). Mixing rate: 50g/100kg of feed.
4. Choline chloride: Contain 60 percent choline. Mixing rate: 50g/100kg of feed.
5. Lysine: Contained 98% lysine. Mixing rate: 50g/100kg of feed.
6. DL-methionine: Contained 98% methionine. Mixing rate: 150g/100kg of feed.

### Statistical Analysis

Data was analysed statistically as described by Snedecor and Cochran (1994). Analysis of variance was used to study the differences among treatment means and they were compared by using Duncans Multiple Range Test (DMRT) as modified by Kramer (1956).

### Result and Discussion

Data pertaining to gut morphology of the experimental birds under different dietary treatments are presented in Table 2.

**Table 2:** Villi height, villi width, crypt depth and villi height: crypt depth of intestine of experimental birds under different dietary treatments

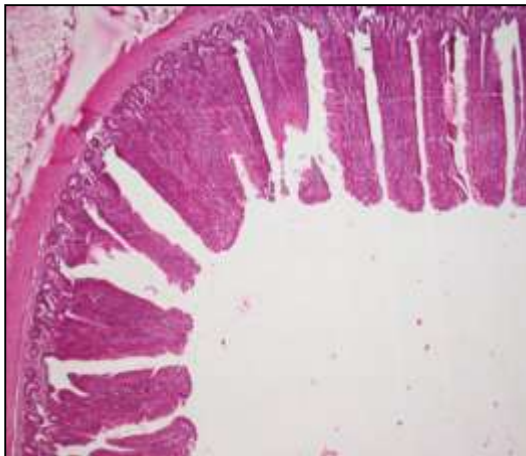
Treatments	Villi height (Micron)	Crypt depth (Micron)	Height : Crypt depth
T <sub>1</sub>	0984.56 <sup>c</sup> ±28.64	190.33 <sup>a</sup> ±9.09	5.44 <sup>c</sup> ±.24
T <sub>2</sub>	0979.93 <sup>c</sup> ±30.69	159.88 <sup>bc</sup> ±4.74	6.30 <sup>bc</sup> ±.28
T <sub>3</sub>	1076.32 <sup>bc</sup> ±48.07	176.57 <sup>ab</sup> ±8.63	6.65 <sup>b</sup> ±.49
T <sub>4</sub>	1104.53 <sup>ab</sup> ±30.46	177.21 <sup>ab</sup> ±5.25	6.44 <sup>b</sup> ±.31
T <sub>5</sub>	1136.42 <sup>ab</sup> ±30.60	143.75 <sup>c</sup> ±4.50	8.12 <sup>a</sup> ±.34
T <sub>6</sub>	1196.72 <sup>a</sup> ±29.67	155.67 <sup>c</sup> ±5.31	7.92 <sup>a</sup> ±.32

*a,b,c* means bearing different superscripts in a column differ significantly ( $P < 0.05$ )

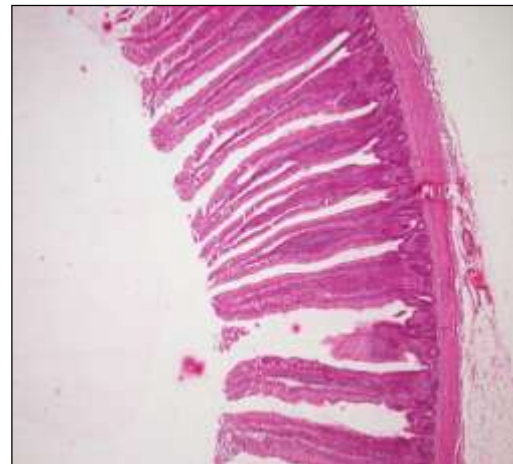Mean villus height of the birds under different dietary treatments ranged from 984.56  $\mu$ m to 1196.72  $\mu$ m. Dietary supplementation of amla fruit powder increased the height of the villi and significant increment was observed in T<sub>6</sub> followed by T<sub>5</sub> and T<sub>4</sub>. Turan and Mahmood (2007) suggested that the liberation of enterocytes from the villus tip cells due to apoptosis generated the large amount of free radicals in villus tip cells. In present study, antioxidants present in amla may effectively scavenge the generated free radicals caused by stress, consequently resulting in improved ileal morphology. Crypt depth under different dietary treatments ranged from 143.75 $\mu$ m to 190.33  $\mu$ m and higher value of crypt depth was obtained in the (T<sub>1</sub>)

group and difference was significantly higher than the amla and antibiotic supplemented group. Height: Depth of intestinal crypts of the birds under different dietary treatments ranged from 5.44 to 8.12 and significant effect on height: depth ratio of intestinal crypts was recorded in the 0.75% amla powder supplemented group (T<sub>5</sub>). The morphometric analysis result of the present study showed that the supplementation of antioxidants increased villus height, but decreased crypt depth in broilers and these results are in agreements with Park *et al.* (2016) who concluded that the supplementation of antioxidants increased villus height but decreased crypt depth in broilers reared under chronic heat stress.

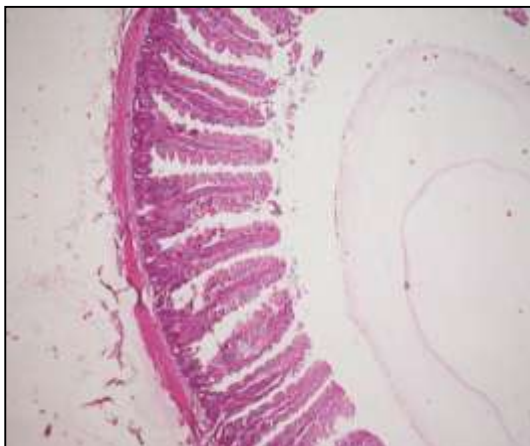### Histological Demonstration of Intestinal Villi



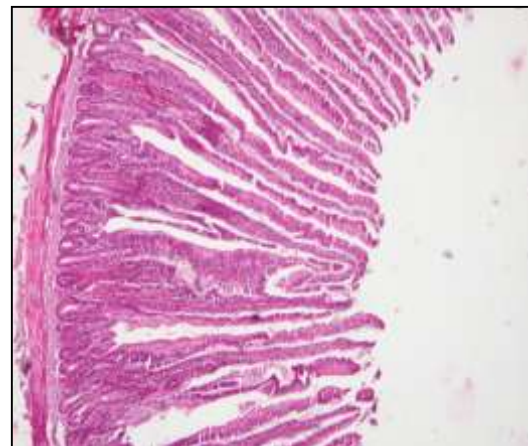
**Fig. 1:** Morphometry of intestinal villi (Control group T<sub>1</sub>)



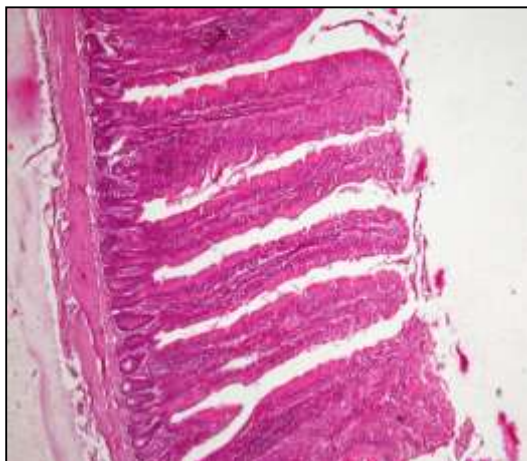**Fig. 2:** Morphometry of intestinal villi (Antibiotic supplemented group T<sub>2</sub>)



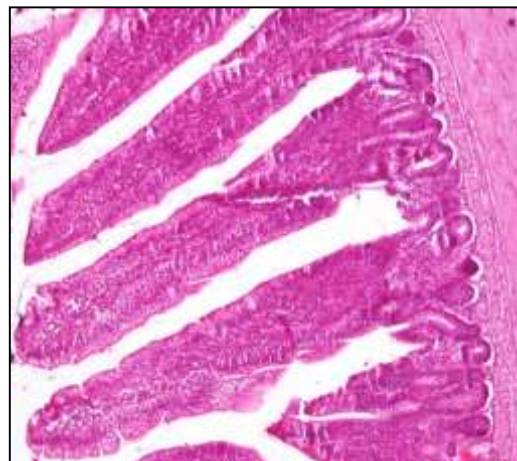**Fig. 3:** Morphometry of intestinal villi (0.25% amla supplemented group T<sub>3</sub>)



**Fig.4:** Morphometry of intestinal villi (0.50% amla supplemented group T<sub>4</sub>)



**Fig. 5:** Morphometry of intestinal villi (0.75% amla supplemented group T<sub>5</sub>)



**Fig. 6:** Morphometry of intestinal villi (1% amla supplemented group T<sub>6</sub>)

Similarly, Rajput *et al.* (2013) reported that villus height was significantly increased in duodenum, jejunum and ileum in curcumin supplemented broilers. Villus width was also significantly increased in duodenum and jejunum while, there was no significant difference in ileum villus width. Furthermore, villus height to crypt depth ratio was significantly increased in all segments of small intestine in curcumin supplemented group. Phenolic compounds administration may reduce gut inflammation, improve digestibility of nutrients and metabolism (Giannenas *et al.*, 2010). The villus height: crypt depth ratio is an indicator of the likely digestive capacity of the small intestine and increase in this ratio corresponds to an increase in digestion and absorption (Montagne *et al.*, 2003). Increased intestinal villi height and the ratio villi height to crypt depth is an indication of the vast area for nutrient absorption and higher absorption function (Siao *et al.*, 2005). Higher villus height, low crypt depth and high villus height /crypt depth ratio are desirable parameters for better absorption of nutrients (Xu *et al.*, 2003). Thinning of the gastrointestinal walls tract may be due to the inhibition of the microbial production of polyamines and volatile fatty acids, known to increase enterocyte turnover rate and activity. This increased net energy committed to maintaining the luminal tissue comes at the expense of more productive purposes such as muscle accretion (Bedford, 2000). Reduced villus height/crypt depth ratio can also indicate presence of toxin, reduced absorption of nutrients, increased secretion in gastrointestinal tract, diarrhoea, reduced disease resistance and lower over-all performance. Enhancement of intestinal activities of trypsin, lipase and amylase (Lee *et al.*, 2004) and improved gut morphological characteristics (Jamroz *et al.*, 2003) are the major mechanisms through which phytoadditives exert their beneficial effect on the nutrient digestibility. Phytoadditives has antibacterial, antioxidant, antistress, gut microflora manipulation, immune enhancement properties and digestive enzymes stimulation could be the probable reasons for the positive effects exerted by them on the growth and health performance of animals (Durrani *et al.*, 2007; Hashemi and Davoodi 2011).

## Conclusion

Based upon the above study, it can be concluded that amla fruit powder can be effectively supplemented as an alternative to antibiotics growth promoter in poultry ration and best results was obtained at 0.75% amla supplementation level (T<sub>5</sub>) with regards to gut morphology. Production of short chain fatty acids by *Lactobacilli* results into effective migration of enterocytes along the tip of villi which enhanced the growth of intestinal villi. In present study, antioxidants present in amla may effectively scavenge the generated free radicals caused by stress, consequently resulting in improved ileal morphology. The villus: crypt depth ratio is an indicator of the likely digestive capacity of the small intestine. Increased villi height is an indicator of increased enzymic digestion thereby providing more surface area for absorption of nutrients.

## Acknowledgments

Authors are thankful for the help and support received from Department of Animal Nutrition and Veterinary pathology for their help in carrying out our research.

## Competing Interests

The author have no competing interests to declare.

## References

1. Anonymous (2015). 4<sup>th</sup> International poultry and livestock Expo, Bangalore.
2. AOAC. (2013). *Official Methods of Analysis*. 16<sup>th</sup>edn. Association of official Analytical Chemists. Arlington Virginia, USA.
3. Bedford, M. R. (2000). Exogenous enzymes in monogastric nutrition—their current value and future benefits. *Animal Feed Science and Technology*. 86(1-2):1-13.
4. BIS (2007). Nutrient Requirements of Poultry IS: 1374. Bureau of Indian Standards New Delhi, India
5. Durrani, F. R., Sultan, A., Ahmed, S., Chand, N., Khattak, F. M., & Durrani, Z. (2007). Efficacy of Aniseed Extract as Immune Stimulant and Growth Promoter in Broiler Chicks. *Pakistan Journal of Biological Sciences*. 10(20):3718-3721.
6. Giannenas, I., Pappas, I. S., Mavridis, S., Kontopidis, G., Skoufos, J., & Kyriazakis, I. (2010). Performance and antioxidant status of broiler chickens supplemented with dried mushrooms (*Agaricus bisporus*) in their diet. *Poultry science*. 89(2): 303-311.
7. Hashemi, S. R., & Davoodi, H. (2011). Herbal plants and their derivatives as growth and health promoters in animal nutrition. *Veterinary research communications*. 35(3):169-180.
8. Jamroz, D., Orda, J., Kamel, C., Wiliczkiwicz, A., Wertelecki, T., & Skorupinska, J. (2003). The influence of phytogenic extracts on performance, nutrient digestibility, carcass characteristics, and gut microbial status in broiler chickens. *Journal of Animal and Feed Sciences*. 12(3): 583-596.
9. Kramer, C.Y. (1956) Examination of multiple range tests to group means with unequal numbers of replication. *Biometrics* 12: 307-310.
10. Lee, K. W., Everts, H., Kappert, H. J., Van Der Kuilen, J., Lemmens, A. G., Frehner, M., & Beynen, A. C. (2004). Growth performance, intestinal viscosity, fat digestibility and plasma cholesterol in broiler chickens fed a rye-containing diet without or with essential oil components. *International Journal Poultry Science*. 3(9):613-618.
11. Mohanty, S., & Rajendran, K. (2003). 2020 vision for Indian poultry industry. *International Journal of Poultry Science*. 2(2):139-143.



12. Montagne, L., Pluske, J. R., & Hampson, D. J. (2003). A review of interactions between dietary fibre and the intestinal mucosa, and their consequences on digestive health in young non-ruminant animals. *Animal feed science and technology*. 108(1-4): 95-117.
13. Park, J. H., Song, T. H., & Kim, I. (2016). Egg production, egg quality, and cecal microbial populations of layers fed diets supplemented with fermented phytogenic feed additive. *Turkish Journal of Veterinary and Animal Sciences*. 40(5): 660-666.
14. Rajput, N., Muhammad, N., Yan, R., Zhong, X., & Wang, T. (2013). Effect of dietary supplementation of curcumin on growth performance, intestinal morphology and nutrients utilization of broiler chicks. *The Journal of Poultry Science*. 50(1): 44-52.
15. Sieo, C. C., Abdullah, N., Tan, W. S., & Ho, Y. W. (2005). Influence of  $\beta$ -glucanase-producing *Lactobacillus* strains on intestinal characteristics and feed passage rate of broiler chickens. *Poultry science*. 84(5): 734-741.
16. Snedecor, G.W., and Cochran, W.G. (1994). *Statistical Methods*, 6<sup>th</sup> edn. Iowa State University Press, Ames, Iowa, USA.
17. Turan, A., & Mahmood, A. (2007). The profile of antioxidant systems and lipid peroxidation across the crypt-villus axis in rat intestine. *Digestive diseases and sciences*. 52(8): 1840-1844.
18. Xu, Z. R., Hu, C. H., Xia, M. S., Zhan, X. A., & Wang, M. Q. (2003). Effects of dietary fructooligosaccharide on digestive enzyme activities, intestinal microflora and morphology of male broilers. *Poultry science*. 82(6):1030-1036.

