



Original Research

Parasitological and Molecular Survey of *Hepatozoon* Infection in Dogs of South-Western Region (Junagadh) of Gujarat, India

Binod Kumar^{1,*}, B. J. Thakre², Joice P Joseph³, Nilima N. Brahmbhatt¹ and Jeemi A. Patel¹

College of Veterinary Science & Animal Husbandry, Junagadh Agricultural University,
Junagadh-362001, Gujarat, INDIA

¹Department of Veterinary Parasitology

²Animal Disease Diagnostic Laboratory

³Department of Veterinary Medicine

*Corresponding author: drkumarbinod@gmail.com

Rec. Date:	Apr 09, 2018 10:43
Accept Date:	Jun 15, 2018 13:40
DOI	10.5455/ijlr.20180409104309

Abstract

Hepatozoon infection in 317 dogs of Junagadh region was surveyed by both microscopically and polymerase chain reaction (PCR). Giemsa stained thin blood smear of five dogs (1.58 %) revealed Gamont stage in the white blood cells. Among these five dogs, two were showing severe symptoms like high temperature (106 °F), congested mucous membrane, enlarge lymph node, aggressive behavior and difficulty to put the legs on ground and they died during treatment. Through PCR, 21 dogs (6.62 %) were found positive for *Hepatozoon* infection, including microscopically positive animals. The 16 dogs, exclusively found positive in PCR test were either symptomless or having mild general health disturbance which were cured by symptomatic treatment. The results indicate the presence of *Hepatozoon* infection in dog of this region.

Key words: Dog, Gamont, *Hepatozoon*, Microscopy, Polymerase Chain Reaction

How to cite: Kumar, B., Thakre, B., Joseph, J., Brahmbhatt, N., & Patel, J. (2018). Parasitological and Molecular Survey of *Hepatozoon* Infection in Dogs of South-Western Region (Junagadh) of Gujarat, India. International Journal of Livestock Research, 8(11), 363-368. doi: 10.5455/ijlr.20180409104309

Introduction

Hepatozoonosis is a tick-borne disease of dog caused by *Hepatozoon* parasite. It is an apicomplexan protozoa from the family Hepatozoidae in the order Adeleorina. The family is having about 300 species found in infecting reptiles, birds and mammals (Smith, 1996). There are two known species of *Hepatozoon* infecting the dogs: *H. americanum* and *H. canis*. Former species is usually reported from new world countries and usually transmitted by *Amblyomma maculatum*, causes distinct type of diseases manifested as fever, lethargy, weight loss, stiffness, sign of pain and in advance case paralysis (Macintire *et al.*, 2001).



Whereas, *H. canis* infection is reported from southern Europe, the Middle East, Africa and Far East countries including India (Rani *et al.*, 2011). The main vector of this disease is well established as *Rhipicephalus sanguineus* (Baneth *et al.*, 2001). Subclinical infection of *H. canis* is very common and clinical form of disease is not well known, usually manifested as anaemia and lethargy. The gametocytic stage of parasite is circulating in white blood cells of infected dog which can be diagnosed by thin blood smear examination.

In India, very few reports are available on the canine hepatozoonosis caused by *H. canis*. Moreover, majority are based on microscopic examination which does not permit reliable identification of the parasite (Rani *et al.*, 2011). Molecular diagnostics based on conventional PCR or other techniques developed during the last few decade, greatly contributed in understanding the spread of this protozoan in canine population. However, these infected carrier dogs place the dog population at risk of disease. Molecular methods such as PCR are considered as more sensitive and specific test for diagnosis of pathogens in blood (Criado-Fornelio *et al.*, 2003), and may be suitable for surveying the canine hepatozoonosis in dogs. Recent publication on tick-borne diseases of canine in India reports, 30 % of dogs are PCR test positive for *Hepatozoon* infection whereas, only 2.3 % infections are detected microscopically (Rani *et al.*, 2011). Accordingly, the aim of the present study was to survey the dog population infected with *Hepatozoon* parasite so that we can take a suitable measure to control the further spread of the infection.

Materials and Methods

The study was conducted in and around Junagadh city of Gujarat. Junagadh is one among the 33 districts of Gujarat, present in south-western region of India. It has an area of about 5092 square KM, having tropical wet and dry climate favour tick growth. The dogs presented at the Veterinary College hospital (TVCC), Junagadh for the treatment, vaccination, deworming, general consultation, etc. are involved in the present study. While physical examination of animals, blood samples were also collected from saphenous vein of dogs for laboratory diagnosis. About 0.5-1 ml of blood was collected from each animal in a vial containing EDTA and kept on ice. For blood smear preparation, drop of blood was smeared on the grease free micro slide, dry and wrapped in a clean paper. Thin blood smear was subjected to Giemsa staining method following the standard protocol. The stained smear was examined under oil immersion lens of compound binocular microscope (100x) for the detection of *Hepatozoon* gamont in white blood cells (WBCs).

Total DNA was isolated from 200 µl of the collected blood sample by GENEJET™ whole blood genomic DNA purification mini kit (Thermo Scientific, USA) as per manufacturer's instructions. Finally, DNA was eluted in 200 µl of elution buffer. Genomic DNA isolated from blood sample found microscopically positive for *Hepatozoon* gamont in WBCs of dog was used as positive control. Genus specific PCR primer directed amplification of target gene in *Hepatozoon spp.* was carried out by PCR using standard protocol.

A 666 bp fragment of the 18S rRNA gene was amplified by using the primers set, HepF (5'ATACATGAGCAAATCTCAAC3') and HepR (5'CTTATTATTCCATGCTGCAG3') (Inokuma *et al.*, 2002). PCR assay was carried out in a final volume of 25 μ L, including 12.5 μ L of 2x Dream Taq Green PCR master mix (Thermo Scientific, USA), 1 μ L each of 10 mM primers, 2 μ L sample DNA isolated from dog blood and 8.5 μ L of nuclease free water. The PCR cycling conditions were set in automated thermal cycler (Applied Bio System, USA) with the following programme: initial denaturation at 95°C for 3 min followed by 35 cycles of denaturation at 94°C for 30 sec, annealing at 57 °C for 30 sec, extension at 72 °C for 45 sec and the final extension at 72 °C for 5 min. The blood samples of dog showed PCR positivity for *Hepatozoon* infection were also subjected for *Babesia* spp. (F- 5' AATACCCCAATCCTGACACAGGG3' and R- 5' TTAAATACGAATGCCCAAC3') and *Ehrlichia canis* (ECF- 5'CAATTATTTATAGCCTCTGGCTCTGGCTATAGGA3' and ECR- 5'TATAGGTACCGTCATTATCTTCCCTAT3') specific PCR test (Cardoso *et al.*, 2008; Murphy *et al.*, 1998). The amplified PCR products were resolved by electrophoresis on a 1.2 % agarose gel containing 0.5 μ g/ml ethidium bromide and visualized using gel documentation system (Vilverlourmat, Bioprint ST4, Germany). Percentage of samples found positive in microscopic examination and polymerase chain reaction was calculated and discussed.

Results

After collection of blood, samples were first tested for microscopic examination of thin blood smear stained with Giemsa stain. Out of 317 blood samples only 5 samples (1.58 %) were found positive for *Hepatozoon* infection and reported to the hospital. Among the five, two were shown high level of parasitaemia i.e., around 30% of leucocytes contains *Hepatozoon* gamont and other three have mild infection (Fig. 1).

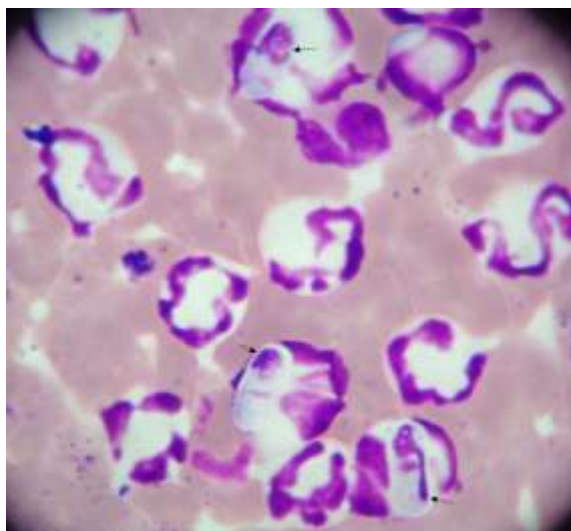


Fig. 1: Gamont stage of *Hepatozoon* spp. seen in polymorphonuclear cells of dog blood stained with Giemsa stain (1000 X).

Clinical symptoms of the two severely infected dogs were recorded as high temperature (106 °F), congested mucous membrane, enlarge lymph node, aggressive behavior and difficulty to put the legs on ground. These dogs were treated with combination of Imidocarb dipropionate and Doxycycline along with supportive treatment but unfortunately they died after showing some improvement. Dogs which is having mild infection were recorded with anorexia and mild fever and responded the treatment.

After microscopic examination, blood samples were processed for *Hepatozoon* specific PCR test where DNA samples from 21 animals, including 5 microscopically positive samples, were reacted with PCR primers and amplicon length of about 666 bp obtained (Fig. 2). The blood samples of dog showed PCR positivity for *Hepatozoon* infection were also subjected for *Babesia* and *Ehrlichia canis* specific PCR test and none were found positive. Some of the animals which were detected *Hepatozoon* positive in PCR test, recorded with non-specific symptoms like loose feaces, anorexia, weakness and some are with mild fever. They all were treated with suitable drugs and cured.

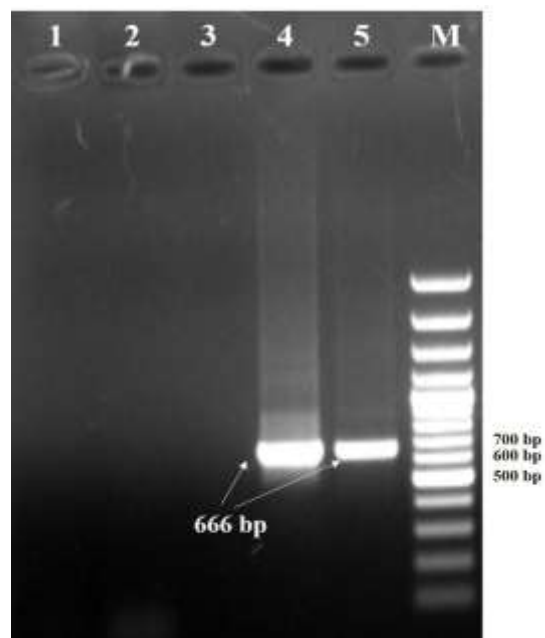


Fig. 2. PCR amplification of 18S rRNA gene of *Hepatozoon* spp. from DNA isolated from blood of dogs. Lane 1-3: DNA samples showing no amplification of targeted gene. Lane 4-5: Positive amplification of about 666 bp of targeted gene. M- DNA ladder.

Discussion

Hepatozoon canis and *H. americanum* are recorded in canines of distinct geographical regions, may be due to distribution of tick/vector and limitation of parasite to geographically isolated host. Globalization and changing climatic conditions, may weaken these restriction. So, suitable diagnostic methods or epidemiological tools are always required for the proper identification of the infectious agents. In the

present study, total five dogs were microscopically diagnosed (1.58 %) as *Hepatozoon* infected. Where two dogs are showing severe clinical symptoms and later died even after giving scheduled drugs (Baneth and Weigler, 1997), other dogs are having mild symptoms and survived after treatment. On the other hand Sakuma *et al* (2009) presented a case report of dog having acute form of hepatozoonosis with anaemia and severe dehydration. He treated the dog with clindamycin and doxycycline (Macintire *et al.*, 2006) and recovery of dog occur. In the present investigation, the symptoms recorded in the two dogs are: high temperature (106 °F), congested mucous membrane, enlarge lymph node, aggressive behavior and difficulty to put the legs on ground. These symptoms are vague and matched somewhat with the symptoms of *H. americanum* infection (Macintire *et al.*, 2001). However, *H. americanum* infection in dogs are not reported from India.

Molecular method like PCR is able to detect 16 more *Hepatozoon* infected dogs. These dogs were either healthy or having different clinical symptoms like anorexia, mild diarrhoea which is cured after symptomatic treatment. Detection of *Hepatozoon* infection in 6.62 % dogs by PCR may be due to very high sensitivity of the test and also detection of other developmental stages sporozoites / merozoites which cannot be detected in blood smear examination. The PCR primer set, HpeF-HepR, were used by various researcher for the detection of canine hepatozoonosis (Inokuma *et al.*, 2002; Sakuma *et al.*, 2009; Otranto *et al.*, 2011; Rani *et al.*, 2011; Cardoso *et al.*, 2014; Aktas *et al.*, 2015). Rani *et al* (2011) recorded 30 % of Indian dogs infected with *H. canis* through PCR test. In Turkey, Aktas *et al* (2015) surveyed 694 dogs for *Hepatozoon* infection and found 22.3 % positive in PCR test whereas only one percent animal showed positive infection microscopically.

Conclusion

In conclusion, our study revealed that dogs of the region is having infection of *Hepatozoon* parasite. The outcome of infection is usually subclinical and sometimes it is clinical and may be fatal.

Acknowledgement

The authors are highly thankful to the officer In-Charge, TVCC, Veterinary College, Junagadh and Principal and Dean, College of Veterinary Science and Animal Husbandry, Junagadh Agricultural University, Junagadh for providing the necessary facilities.

Conflict of Interest

The authors declare that there is no conflict of interests.

References

1. Aktas, M., Ozubek, S., Altay, K., Balkaya, I., Utuk, A.E., Kirbas, A., Simsek, S., Dumanlı, D. (2015). A molecular and parasitological survey of *Hepatozoon canis* in domestic dogs in Turkey. *Veterinary Parasitology*, 209, 264–267.
2. Baneth, G., Weigler, B. (1997). Retrospective case-control study of hepatozoonosis in dogs in Israel. *Journal of Veterinary Internal Medicine*, 11, 365-370.
3. Baneth, G., Samish, M., Alekseev, E., Aroch, I., Shkap, V. (2001). Transmission of *Hepatozoon canis* to dogs by naturally-fed or percutaneously-injected *Rhipicephalus sanguineus* ticks. *Journal of Parasitology*, 87, 606–611.
4. Criado-Fornelio, A., Martinez-Marcos, A., Buling-Saraña, A., Barba-Carretero, J.C. (2003). Molecular studies on *Babesia*, *Theileria* and *Hepatozoon* in southern Europe Part II. Phylogenetic analysis and evolutionary history. *Veterinary Parasitology*, 114, 173–194.
5. Cardoso, L., Costa, A., Tuna, J., Vieira, L., Eyal, O., Yisaschar-Mekuzas, Y., Baneth, G. (2008). *Babesia canis canis* and *Babesia canis vogeli* infections in dogs from northern Portugal. *Veterinary Parasitology*, 156, 199-204.
6. Cardoso, L., Cortes, H.C.E., Eyal, O., Reis, A., Lopes, A.P., Vila-Vicosa, M.J., Rodrigues, P.A., Baneth, G. (2014). Molecular and histopathological detection of *Hepatozoon canis* in red foxes (*Vulpes vulpes*) from Portugal. *Parasites & Vectors*, 7, 113-118.
7. Inokuma, H., Okuda, M., Ohno, K., Shimoda, K., Onishi, T. (2002). Analysis of the 18S rRNA gene sequence of a *Hepatozoon* detected in two Japanese dogs. *Veterinary Parasitology*, 106, 265–271.
8. Murphy, G.L., Ewing, S.A., Whitworth, L.C., Fox, J.C., Kocan, A.A. (1998). A molecular and serologic survey of *Ehrlichia canis*, *Ehrlichia chaffeensis* and *E. ewingii* in dogs and ticks from Oklahoma. *Veterinary Parasitology*, 79, 325-339.
9. Macintire, D.K., Vincent-Johnson, N.A., Kane, C.W., Lindsay, D.S., Blagburn, B.L., Dillon, A.R. (2001). Treatment of dogs infected with *Hepatozoon americanum*: 53 cases (1989–1998). *Journal of American Veterinary Medical Association*, 218, 77–82.
10. Macintire, D.K., Vincent-Johnson, N.A., Craig, T.M. (2006). Hepatozoonosis. pp. 705–711. In: *Infectious Diseases of the Dog and Cat*, 3rd ed. (Greene C. E. ed.), Saunders, Philadelphia.
11. Otranto, D., Dantas-Torres, F., Weigl, S., Latrofa, M.S., Stanneck, D., Decapariis, D., Capelli, G., Baneth, G. (2011). Diagnosis of *Hepatozoon canis* in young dogs by cytology and PCR. *Parasite & Vectors*, 4, 55-62.
12. Rani, P.A.M.A., Irwin, P.J., Coleman, G.T., Gatne, M., Traub, R.J. (2011). A survey of canine tick-borne diseases in India. *Parasite and Vectors*, 4, 141-151.
13. Smith, T.G. (1996). The genus *Hepatozoon* (Apicomplexa: Adeleina). *Journal of Parasitology*, 82, 565-585.
14. Sakuma, M., Nakahara, Y., Suzuki, H., Uchimura, M., Sekiya, Z., Setoguchi, A., Endo, Y. (2009). A case report: a dog with acute onset of *Hepatozoon canis* infection. *Journal of Veterinary Medical Science*, 71, 835-838.