

A Case Report of Hydatid Disease in Deccani Sheep

Ravikumar Yadala^{1*}, G. Ramesh², B. Mahesh², G. K. Sawale³ and D. Madhuri⁴

¹Assistant Professor, Department of Veterinary Pathology, College of Veterinary Science, Rajendranagar, Hyderabad, Telangana, INDIA

²PG Scholar, Department of Veterinary Pathology, College of Veterinary Science, Rajendranagar, Hyderabad, Telangana, INDIA

³Assistant Professor, Department of Veterinary Pathology, Bombay Veterinary College, Mumbai, Maharashtra INDIA

⁴Professor and University Head, Department of Veterinary Pathology, College of Veterinary Science, Korutla, Jagtial, Telangana, INDIA

*Corresponding Author: ravikumaryadala@gmail.com

How to cite this paper: Yadala, R., Ramesh, G., Mahesh, B., Sawale, G. K. & Madhuri, D. (2021). A Case Report of Hydatid Disease in Deccani Sheep. *International Journal of Livestock Research*, 11(1), 210-213. <http://dx.doi.org/10.5455/ijlr.20201010063957>

Received : Oct 10, 2020
Accepted : Nov 04, 2020
Published : Jan 31, 2021

Copyright © Yadala *et al.*, 2021

This work is licensed under the Creative Commons Attribution International License (CC BY 4.0). <http://creativecommons.org/licenses/by/4.0/>



Abstract

Hydatid disease was diagnosed in a Deccani sheep during postmortem examination which revealed hydropericardium, gelatinization of fat, different sized hydatid cysts in lungs and liver. Cysts were filled with clear fluid, ranges from 10ml to 25ml. The size of cyst varied from 2 cm to 3 cm in diameter. Histopathological section of the affected lungs and liver revealed laminated hyaline layer surrounded by thick coat of granulation tissue causing fibrosis and infiltration of leucocytes. The adjoining areas of the cysts showed alveolar emphysema and vascular congestion in lung and progressive focal pressure atrophic lesions with vacuolar degeneration in the effected lungs and liver. In the present case, the animals were let loose for grazing, which had access to stray dogs and results into maintenance of parasites or parasitic larvae or ova in the environment. Based on the history, gross and microscopical examination of the organs, it was diagnosed as hydatid disease.

Keywords: Deccani Sheep, Hydatid Disease, Hydatid Cyst, Liver, Lungs

Introduction

Hydatid disease / Hydatidosis is a worldwide zoonotic condition / disease caused by the larval stage of *Echinococcus granulosus*, a small tape worm of dogs. The life cycle of *E. granulosus* involves two different hosts. The adult parasites are found in intestine of dog and excrete the eggs into the faeces. Sheep and goat act as intermediate host (Soulsby, 1982). The development of hydatid disease is by ingestion of the eggs while grazing on pasture, soil or drinking water which were contaminated by faeces of infected dog (Naik *et al.*, 2018). Apart from animals, humans could also be infected through ingestion of contaminated water or vegetables (Ahmadi and Meshkehkar, 2011). Hence, it is considered as one of the emerging and important zoonotic disease. Present report describes a case of hydatid disease in a Deccani sheep.

Materials and Methods

Hydatid disease was diagnosed during routine necropsy examination of Deccani sheep aged 2yrs old. Cysts on visceral organs were subjected to detailed examination. Lung and liver tissues were collected and fixed in 10% neutral buffered formalin (NBF) soon after necropsy. The tissues were dehydrated in different alcohol concentrations (70, 80, 95 and 100%). The processed tissues were cleared in xylene and embedded in paraffin for preparation into fine blocks. Blocks were sectioned with a microtome to a size of 5 μ m, afterwards they were dewaxed and the tissue sections were stained using haematoxylin and eosin (H and E) stain (Bancroft *et al.*, 1990).

Result and Discussion

Grossly, the animal was weak and pale (Fig.1). Postmortem examination revealed hydropericardium and gelatinization of fat (Fig.2). Different sized hydatid cysts were mainly found in the lungs and liver and filled with a clear fluid, ranges from 10ml to 25ml and having hard membrane surrounding the cysts (Fig. 3 and 4). The size of cyst varied from 2 cm to 3 cm in diameter, they were either protruding from the surface or found deep in lung or liver parenchyma. The histopathological section of the affected lungs revealed laminated membrane granulation tissue and collapsed adjacent tissue and infiltration of leucocytes in adjoining areas (Fig. 5 and 6). These finding in different visceral organs were also in accordance with the others findings (Varma and Ahluwalia 1990; Godara *et al.*, 2014). Who also opined that the time of diagnosis of latent hydatidosis in the affected animals using advanced molecular techniques would help to reduce the infection prevalence in dogs and subsequently in the food animals. Proper disposal of dead animal will also reduce the chances of getting contaminated carcass to dogs and there by reduces the chances of spreading the infection (Erbeto *et al.*, 2010; Sangaram and Lalitha John, 2014). In the present study, case was diagnosed as hydatid disease in Deccani sheep based on clinical signs, detailed gross and histopathological examination.



Figure 1: Pale mucous membranes

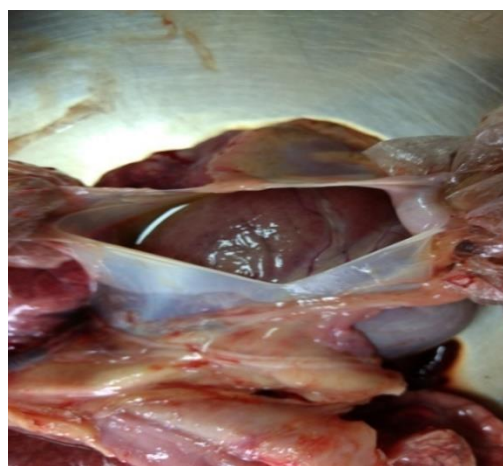

Figure 2: Hydropericardium

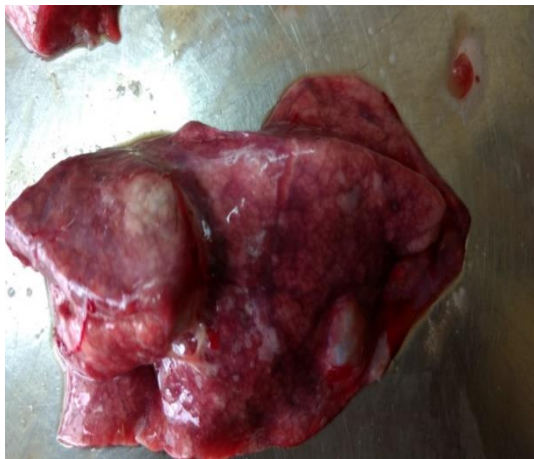

Figure 3: Lung showing cyst of varied size

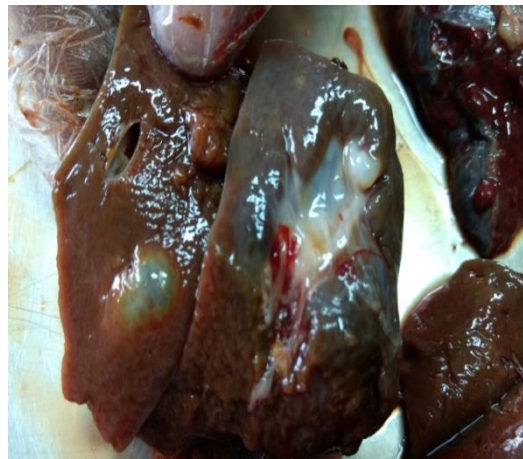


Figure 4: Liver showing cyst of varied size

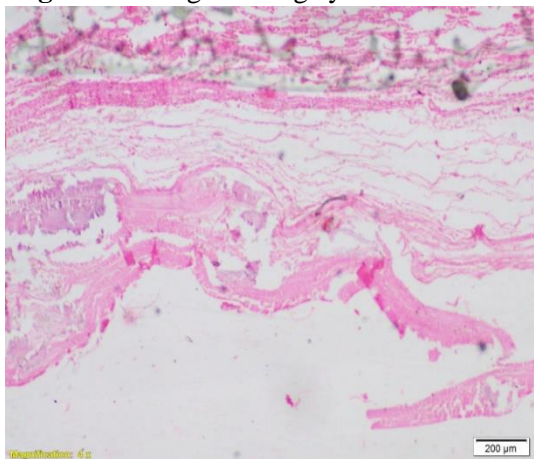


Figure 5: Hydatid cyst- Section of lung showing continuous laminated membrane granulation tissue and collapsed adjacent tissue (H&E x 40X)

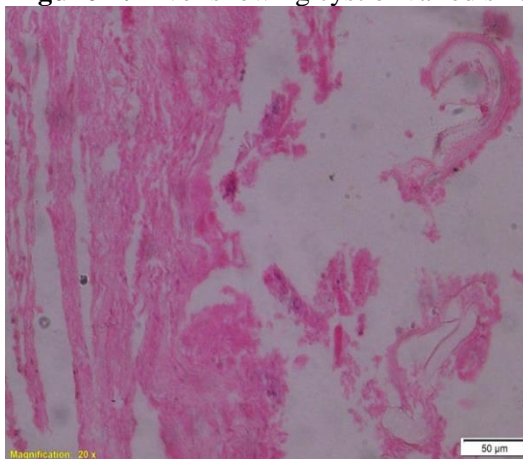


Figure 6: Section of lung showing continuous laminated membrane fibrous tissue capsule (H&E x200X)

Acknowledgement

The authors are thankful to the PV Narsimha Rao Telangana Veterinary University for providing support and necessary facilities to carry out the work.

Conflict of Interests

There is no conflict of interest.

Publisher Disclaimer

IJLR remains neutral concerning jurisdictional claims in published institutional affiliation.

References

1. Ahmadi, N. A. and Meshkehkar, M. (2011). An abattoir-based study on the prevalence and economic losses due to cystic echinococcosis in slaughtered herbivores in Ahwaz, south-western. *Iranian Journal of Helminthology*. 85:33–39.
2. Bancroft, J.D., Stevens, A. and Turner D. (1990). *Theory and practice of histological technique*. 3rd edition. Churchill, Livingstone, Edinburgh, London. Pp. 726.
3. Erbetto, K., Zewde, G. and Kumsa, B. (2010) Hydatidosis of sheep and goats slaughtered at Addis Ababa Abattoir: prevalence and risk factors. *Tropical Animal Health Production*. 42:803–805.

4. Godara, R., Katoch,R. and AnishYadav. (2014). Hydatidosis in goats in Jammu. *Indian Journal of Parasitic Diseases*. 38(1):73–76.
5. Naik, G., Bhandurje, M., Sawale, G., Kommu, S., Ravikumar, Y., Madhuri, D., Chandravati, T. and Lakshman, M. (2018). Occurrence of Hydatidosis in Small Ruminants. *International Journal of Livestock Research*. 8(3):292-295
6. Sangaram, A. and Lalitha John. (2014). Prevalence of Hydatidosis in Sheep and Goats In and around Chennai. Incidence of hydatidosis in slaughtered sheep and goat. *Tamilnadu Journal of Veterinary and Animal Sciences*. 5 (5) 208-210.
7. Soulsby E.J.L. (1982). Helminths, arthropods and protozoa of domesti- cated animals, 7th Edition. Bailliere and Tindal, London, pp 119–125.
8. Varma, T. K. and Ahluwalia, S. S. (1990). Prevalence of *Echinococcus granulosus* infection in domestic animals of western and central Uttar Pradesh. *Journal of Veterinary Parasitology*. 4:67–69.
