



## Paraquat (PQ) Induced Morphometric and Gross Pathological Changes in Target Organs: Ameliorative Effect of Vitamin C in Wistar Rats

K. B. Ashok Kumar Reddy<sup>1\*</sup>, M. Jeevanalatha<sup>2</sup>, M. Lakshman<sup>1</sup> and M. Usha Rani<sup>3</sup>

<sup>1</sup>Department of Veterinary Pathology, College of Veterinary Science, Rajendranagar, Hyderabad, Telangana, INDIA

<sup>2</sup>Department of Veterinary Pathology, College of Veterinary Science, Mamnoon, Warangal, Telangana, INDIA

<sup>3</sup>Department of Veterinary Pharmacology & Toxicology, College of Veterinary Science, Rajendranagar, Hyderabad, Telangana, INDIA

\*Corresponding Author: [iashok0409@rediffmail.com](mailto:iashok0409@rediffmail.com)

**How to cite this paper:** Reddy, K B., Jeevanalatha, M., Lakshman, M., & Usha Rani, M. (2020). Paraquat (PQ) Induced Morphometric and Gross Pathological Changes in Target Organs: Ameliorative Effect of Vitamin C in Wistar Rats. *International Journal of Livestock Research*, 10(6), 141-148. doi:

<http://dx.doi.org/10.5455/ijlr.20200422035742>

**Received** : Apr 22, 2020  
**Accepted** : May 22, 2020  
**Published** : Jun 30, 2020

Copyright © Reddy *et al.*, 2020

This work is licensed under the Creative Commons Attribution International License (CC BY 4.0). <http://creativecommons.org/licenses/by/4.0/>



### Abstract

Forty-eight male albino Wistar rats were randomized into four groups consisting of twelve in each. Group 1 served as control, while group 2 and 4 were administered with paraquat (40 mg/kg b.wt). Additionally, group 4 also received vitamin C (250 mg/kg b.wt). Group 3 was maintained as the vitamin C control (dose as above). The treatment regimens were administered by oral gavage once daily for a period of twenty-one days and the rats were sacrificed on 7th and 21st day of experiment. Group 2 showed significantly ( $P < 0.05$ ) increased absolute lungs weight on 21st day and significantly ( $P < 0.05$ ) decreased absolute liver weight on 7th day and non-significant decrease in absolute kidneys weight on 7th and 21st day of experiment. Grossly, group 2 revealed oedema, emphysema, diffused haemorrhages and congestion of lungs, shrunken and congested liver and congested kidneys. However, vitamin C supplementation had shown a remarkable protection against the parameters investigated.

**Keywords:** Gross Pathology, Organ Weights, Paraquat, Vitamin C

## Introduction

Paraquat (1, 1'- dimethyl- 4,4'- bipyridilium dichloride, PQ) is a non-selective nitrogen herbicide for broadleaf weed control and it is highly toxic compound for both humans and animals (Sun *et al.*, 2011 and Guo *et al.*, 2015). The PQ induced toxicity is mainly due to generation of reactive oxygen species (ROS) through sustained redox-cycling effect, resulting in oxidative stress-related insults such as lipid peroxidation of cellular membranes (Chang *et al.*, 2009). The median lethal dose (LD<sub>50</sub>) of PQ after per oral (PO) administration was 95 (79-114) mg/kg b.wt in *Wistar* rats (Sharp *et al.*, 1972). Lung is the major target organ of PQ poisoning due to its accumulation through highly developed polyamine uptake system, resulting in acute respiratory distress syndrome (ARDS), acute, subacute lung injury and pulmonary fibrosis (Hemmati *et al.*, 2002; Huang *et al.*, 2005, Mainwaring *et al.*, 2006 and Lakshman *et al.*, 2017). The PQ also damage other organs such as liver, kidneys, heart and central nervous system (Khodayar *et al.*, 2014). The fatality rates of PQ poisoning are very high due to lack of effective treatments (Hu *et al.*, 2017) and hence, there is a need to study the effective antidotes against PQ induced toxicity. An emphasis has been placed on the use antioxidants as a treatment for PQ poisoning to repel oxidant induced cellular damage (Suntres, 2002). Vitamin C is an effective antioxidant which has the prospective to scavenge oxygen free radicals (Shahzad *et al.*, 2017). The current investigation was carried out in experimental rats to assess the effectiveness of vitamin C on PQ induced morphometric and gross pathological changes in target organs.

## Materials and Methods

### Experimental Animals

Forty-eight male albino *Wistar* rats weighing 200-250 grams were procured from Sanzyme Laboratories Ltd., Hyderabad. The rats were housed in solid bottom polypropylene cages at Ruska Labs, Hyderabad and were maintained in controlled environment (20-22°C) throughout the course of experiment. Sterile husk was used as standard bedding material. All the rats were provided with standard pellet diet procured from Vyas Labs, Uppal, Hyderabad and deionized water at *ad libitum* throughout the experimental period. The experiment was carried out according to the guidelines and prior approval of Institutional Animal Ethics Committee (IAEC-No.02-2019).

### Drugs and Chemicals

Paraquat (Gramoxone® - 24% w/v solution) was procured from Seed Research and Technology Center, Professor Jayashankar Telangana State Agriculture University, Rajendranagar, Hyderabad which was manufactured by Syngenta India Ltd. Delhi. Vitamin C as L-Ascorbic acid was obtained from S.D. Fine-Chem Ltd., Mumbai, India.

### Experimental Design

A total of 48 male albino *Wistar* rats were randomly divided into four groups consisting of twelve animals in each.

Group 1 - Control

Group 2 – PQ (@ 40 mg/kg b.wt)

Group 3 – Vitamin C (@250 mg/kg b.wt)

Group 4 - PQ (@40 mg/kg b.wt) + Vitamin C (@ 250 mg/kg b.wt)

The dose regimens were administered per os (p.o.) once daily for a period of three weeks. The rats were monitored for clinical signs and death.

### Organ Morphometry and Gross Pathology

On day 7<sup>th</sup>, six (6) rats from each group and remaining on day 21<sup>st</sup> of experiment were sacrificed by gaseous anesthesia (chloroform) and a detailed necropsy examination was carried out as per standard procedure (Feinstein, 2000). The target organs (lungs, liver and kidneys) from all the animals were weighed using electronic balance and gross lesions were noted.

## Statistical Analysis

Data obtained (organ weights) was subjected to statistical analysis by applying one-way ANOVA and using statistical package for social sciences (SPSS) version 25.0. Differences between the means were tested by using Duncan's multiple comparison tests and significance level was set at  $P < 0.05$  (Snedecor and Cochran, 1994).

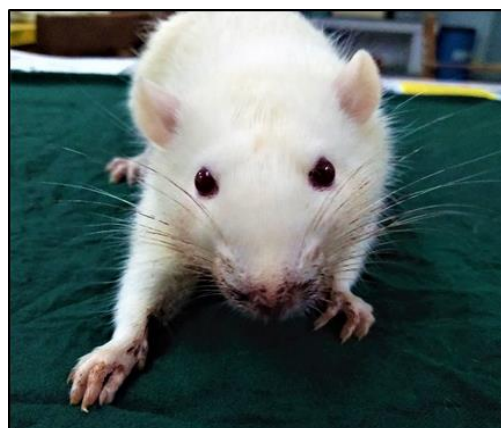## Results and Discussion

### Clinical Signs

Anorexia, lethargy, body weight loss, tachypnea, respiratory distress with squeaking sounds, wet rales, piloerection, back arching posture and bloody nasal discharges were observed in group 2 rats during 13<sup>th</sup> to 21<sup>st</sup> day of experiment whereas other groups (1, 3 and 4) were normal (Fig. 1 and 2). However, no mortalities were recorded during the experimental period.



**Figure 1:** Group 2 rat on 13<sup>th</sup> day showing bloody nasal discharges and back arching posture



**Figure 2:** Group 2 rat on 19<sup>th</sup> day showing blood staining around nostrils, mouth and on medial surface of fore legs

The clinical signs noticed in the present experiment are in agreement with the earlier findings of Lalruatfela *et al.* (2014) and Junbo *et al.* (2017). In the present study, decreased body weights in toxic group were similar to the observations of Reddy *et al.* (2019). Group 4 rats did not manifest any toxic signs which signify the ameliorative effect of vitamin C over highly toxic PQ.

### Organ Morphometry

- a) Significantly ( $P < 0.05$ ) higher mean values of absolute lung weights were recorded in group 2 ( $2.82 \pm 0.06$ ) and group 4 ( $2.45 \pm 0.09$ ) when compared to group 1 ( $2.10 \pm 0.13$ ) and group 3 ( $2.07 \pm 0.04$ ) rats on 21<sup>st</sup> day whereas on 7<sup>th</sup> day of experiment, the mean values were insignificant among all group of rats (Table 1).

**Table 1:** Absolute lungs weight (g) in different groups

Group	Day 7	Day 21
Group 1	$2.06 \pm 0.08$	$2.10 \pm 0.13^c$
Group 2	$1.92 \pm 0.09$	$2.82 \pm 0.06^a$
Group 3	$2.04 \pm 0.04$	$2.07 \pm 0.04^c$
Group 4	$1.95 \pm 0.08$	$2.45 \pm 0.09^b$
P Value	NS	*

Values are Mean  $\pm$  SE (n=6); One-way ANOVA Means with different superscripts in a column differ significantly at  $P < 0.05$  (\*)

These results were in accordance with the earlier studies of Shopova *et al.* (2007) and Yang *et al.* (2015). According to Gardiner (1972), the PQ induced destruction of surfactant producing type II cells results in increased surface tension within the alveolar cavity and it draws fluid from capillaries into the cavity to produce oedema and this

could be the reason for increased lung weights in the present experiment.

- b) Significantly ( $P < 0.05$ ) decreased mean values of absolute liver weights were recorded in group 2 ( $7.10 \pm 0.21$ ) when compared with group 1 ( $8.69 \pm 0.24$ ) and group 3 ( $8.35 \pm 0.17$ ) whereas group 4 ( $7.71 \pm 0.59$ ) mean values were insignificantly varied with all other groups (1, 2 and 3) on 7<sup>th</sup> day of experiment (Table 2).

**Table 2:** Absolute liver weight (g) in different groups

Group	Day 7	Day 21
Group 1	$8.69 \pm 0.24^a$	$9.34 \pm 0.25$
Group 2	$7.10 \pm 0.21^b$	$9.19 \pm 0.35$
Group 3	$8.35 \pm 0.17^a$	$9.47 \pm 0.24$
Group 4	$7.71 \pm 0.59^{ab}$	$9.28 \pm 0.52$
P Value	*	NS

Values are Mean  $\pm$  SE (n=6); One-way ANOVA Means with different superscripts in a column differ significantly at  $P < 0.05$  (\*)

These findings were similar to the earlier observations of Lalruatfela *et al.* (2014). In the present study, decreased liver weights could be due to hepatocyte degeneration and subsequent fibrous tissue proliferation. Gross pathological changes in the present study like shrunken liver on day 7<sup>th</sup> might contribute to significant reduction in the absolute liver weight on day 7<sup>th</sup> of experiment.

- c) The mean values of absolute kidneys weight were numerically decreased in group 2 ( $1.71 \pm 0.06$  and  $2.00 \pm 0.11$ ) as compared to group 1 ( $1.76 \pm 0.04$  and  $2.11 \pm 0.16$ ), group 3 ( $1.74 \pm 0.04$  and  $2.05 \pm 0.02$ ) and group 4 ( $1.79 \pm 0.10$  and  $2.03 \pm 0.11$ ) on 7<sup>th</sup> and 21<sup>st</sup> day of experiment (Table 3).

**Table 3:** Absolute kidneys weight (g) in different groups

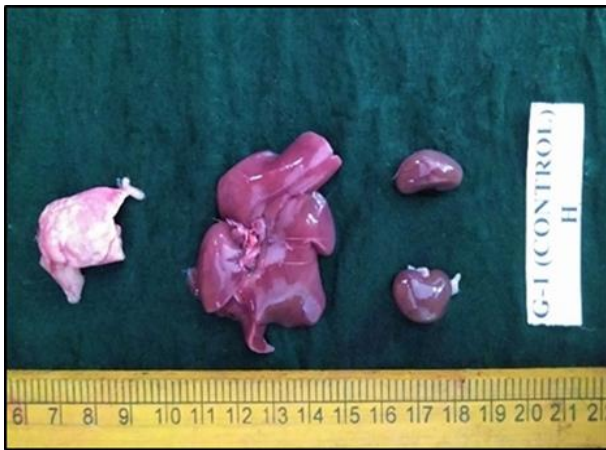Group	Day 7	Day 21
Group 1	$1.76 \pm 0.04$	$2.11 \pm 0.16$
Group 2	$1.71 \pm 0.06$	$2.00 \pm 0.11$
Group 3	$1.74 \pm 0.04$	$2.05 \pm 0.02$
Group 4	$1.79 \pm 0.10$	$2.03 \pm 0.11$
P Value	NS	NS

Values are Mean  $\pm$  SE (n=6); One-way ANOVA Means with different superscripts in a column differ significantly at  $P < 0.05$  (\*)

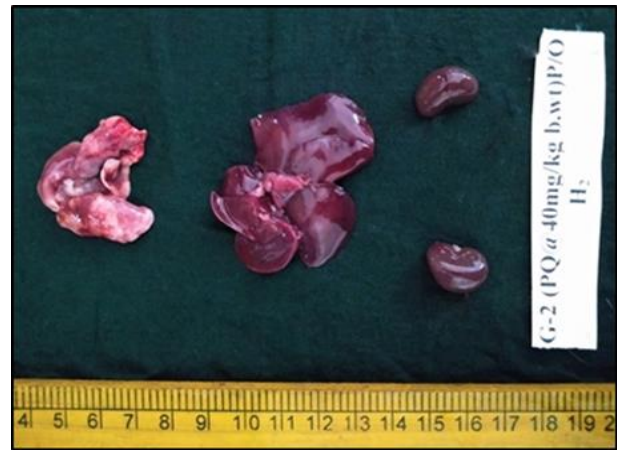The observations are coinciding with the earlier studies of Lalruatfela *et al.* (2014). Non-significant decline in kidney weights in the present study might be due to degeneration and necrosis of functional units. In the present experiment, an improved value of absolute lungs, liver and kidneys weight in group 4 as compared to group 2 indicating the protective role of vitamin C by reducing tissue oxidative damage.

### Gross Pathology

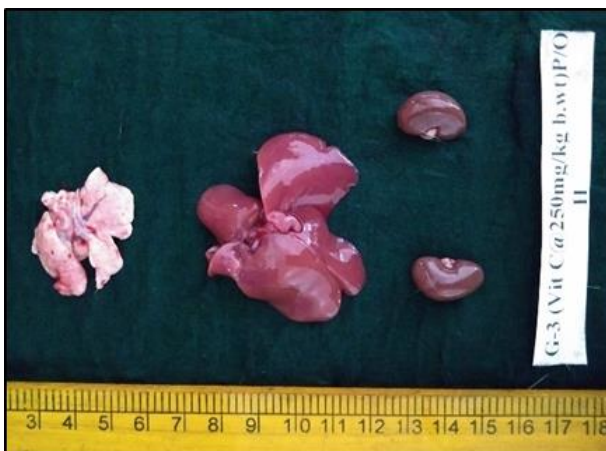Rats were sacrificed on 7<sup>th</sup> and 21<sup>st</sup> day of experiment and gross lesions if any were recorded in lungs, liver and kidneys. Group 1 showed normal appearance of lungs, liver and kidneys on 7<sup>th</sup> and 21<sup>st</sup> day of experiment (Fig. 3 and 7). In group 3, except mild emphysema of lungs on day 21<sup>st</sup> there were no other abnormalities detected in target organs during 7<sup>th</sup> and 21<sup>st</sup> day of experiment (Fig. 5 and 9). Grossly, group 2 lungs showed moderate congestion and mild emphysematous areas on day 7<sup>th</sup> whereas diffuse haemorrhages, severe oedema and congestion were noticed on day 21<sup>st</sup> of experiment. Macroscopically, group 2 liver and kidneys showed moderate congestion on day 7<sup>th</sup> and similar changes but with more severity on day 21<sup>st</sup> of experiment (Fig. 4 and 8). Gross pathological changes of group 4 lungs include mild emphysema with focal haemorrhagic spots on 7<sup>th</sup> and 21<sup>st</sup> day of experiment. Additionally, mild oedema was also observed on 21<sup>st</sup> day of experiment whereas liver and kidneys showed mild congestion on 7<sup>th</sup> and 21<sup>st</sup> day of experiment (Fig. 6 and 10).



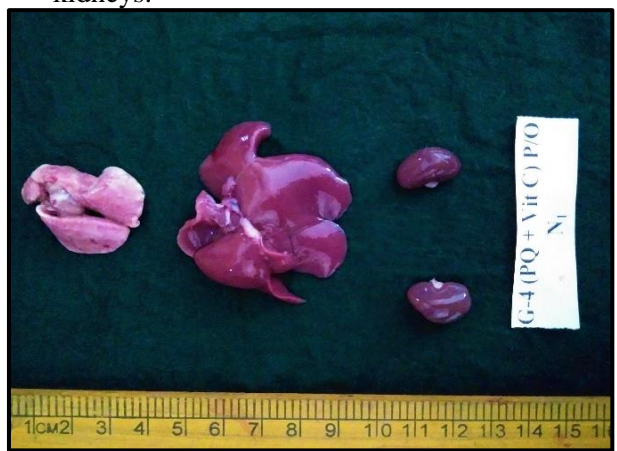**Figure 3:** Group 1 rat on 7<sup>th</sup> day showing normal appearance of lungs, liver and kidneys.



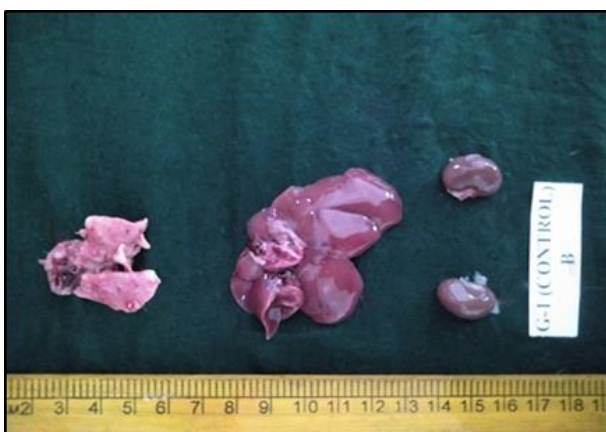
**Figure 4:** Group 2 rat on 7<sup>th</sup> day showing moderate congestion and mild emphysematous areas of lungs, shrunken and moderately congested liver and moderately congested kidneys.



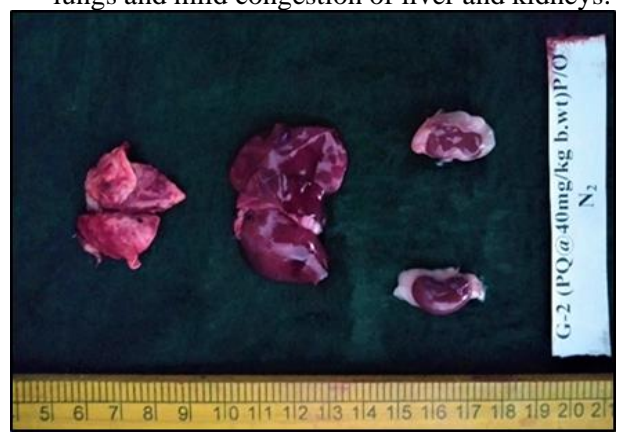**Figure 5:** Group 3 rat on 7<sup>th</sup> day showing normal appearance of lungs, liver and kidneys.



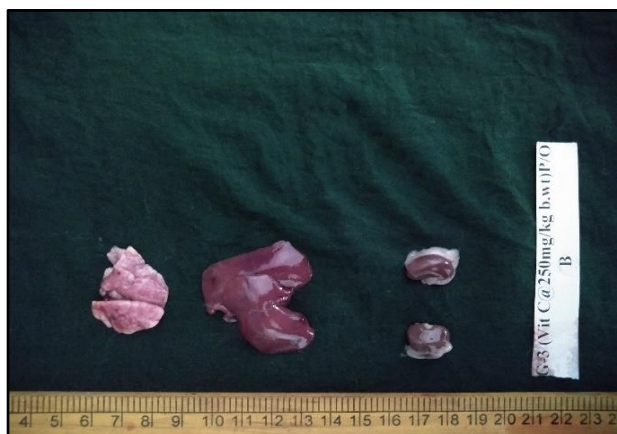**Figure 6:** Group 4 rat on 7<sup>th</sup> day showing mild emphysema with focal haemorrhagic spots on lungs and mild congestion of liver and kidneys.



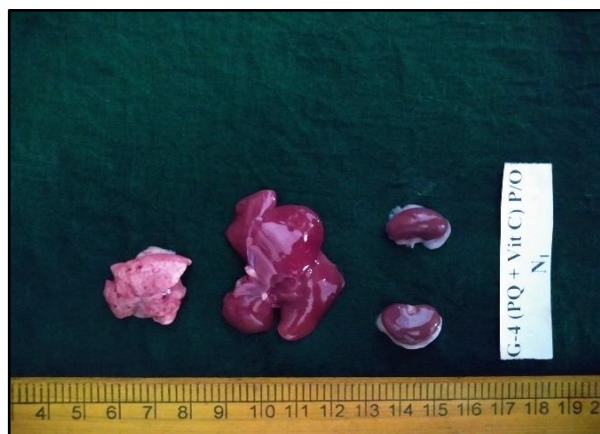
**Figure 7:** Group 1 rat on 21<sup>st</sup> day showing normal appearance of lungs, liver and kidneys.



**Figure 8:** Group 2 rat on 21<sup>st</sup> day showing diffuse haemorrhages, severe oedema and congestion of lungs, severely congested liver and kidneys.



**Figure 9:** Group 3 rat on 21<sup>st</sup> day showing mild emphysema of lungs and normal appearance of liver and kidneys.



**Figure 10:** Group 4 rat (G-IV) on 21<sup>st</sup> day showing mild oedema, mild emphysema with focal haemorrhagic spots on lungs and mild congestion of liver and kidneys.

In the present study, major gross changes were noticed in lungs which could be due to active uptake of PQ by clara, type I and II pneumocytes through the highly developed polyamine uptake system (Dinis-oliveira *et al.*, 2009). Lung oedema could be due to free radical mediated oxidative damage to alveolar epithelium and capillary endothelial cells. Similar gross changes in lungs were documented by Lakshman *et al.* (2017). In the present study, gross pathological alterations might be due to vascular changes such as congested blood vessels and distended sinusoids with haemorrhages (Reddy, 2019) and the findings were similar to the earlier studies of Chohan *et al.* (2010) and Divya (2010). Kidney is the second major target organ affected after lungs in PQ poisoning and in support, renal changes observed by Reddy (2019) which include congested blood vessels and intertubular haemorrhages also might contribute to gross kidney changes in the present experiment. Similar macroscopic changes in kidneys were expressed by Lalruatfela *et al.* (2014) and Tan *et al.* (2015). The minor gross changes noticed in group 3 lungs could be due to the effect of exogenous vitamin C supplementation. In group 4, the gross changes noticed in target organs were minimal as compared to group 2 which could be due to ameliorative effect of vitamin C.

## Conclusion

Based on the results obtained, it can be concluded that co-treatment with vitamin C had shown a prominent role of amelioration on PQ induced morphometric and gross pathological changes in target organs possibly *via* antioxidant defence mechanism.

## Acknowledgement

We thankfully recognize the accessibility of the necessary facilities provided by P V Narsimha Rao Telangana Veterinary University for smooth conduct of the clinical research.

## Conflict of Interests

There is no conflict of interest.

## Publisher Disclaimer

IJLR remains neutral concerning jurisdictional claims in published institutional affiliation.

## References

1. Chang, X., Shao, C., Wu, Q., Wu, Q., Huang, M. and Zhou, Z. (2009). Pyrrolidine dithiocarbamate attenuates paraquat-induced lung injury in rats. *BioMed Research International*, 2009, 8.
2. Chohan, M. S., Tahir, M., Lone, K. P., Sami, W. and Munir, B. (2010). Paraquat induced hepatotoxicity in albino mice. *Pakistan Journal of Zoology*, 42(1), 69- 73.

3. Dinis-Oliveira, R. J., de Pinho, P. G., Santos, L., Teixeira, H., Magalhães, T., Santos, A., Bastos, M. L., Remiao, F., Duarte, J. A. and Carvalho, F. (2009). Postmortem analyses unveil the poor efficacy of decontamination, antiinflammatory and immunosuppressive therapies in paraquat human intoxications. *PLoS one*, 4(9), e7149.
4. Divya, V. S. (2010). *Studies on the ameliorative effect of vitamin E on paraquat toxicity in rats* (Master's thesis, Kerala Veterinary and animal Sciences University, Mannuthy). Retrieved from <https://krishikosh.egranth.ac.in/handle/1/5810026818>.
5. Feinstein, R. E. (2000). In: Post mortem procedures in Handbook of Laboratory Animal Science, ed by Svendsen. P. and Hau, J, 1, 383-396.
6. Gardiner, A. J. S. (1972). Pulmonary oedema in paraquat poisoning. *Thorax*, 27(1), 132-135.
7. Guo, F., Sun, Y. B., Su, L., Li, S., Liu, Z. F., Li, J., Hu, X. T. and Li, J. (2015). Losartan attenuates paraquat-induced pulmonary fibrosis in rats. *Human and Experimental Toxicology*, 34(5), 497- 505.
8. Hemmati, A. A., Nazari, Z., Motlagh, M. E. and Goldasteh, S. (2002). The role of sodium cromolyn in treatment of paraquat-induced pulmonary fibrosis in rat. *Pharmacological Research*, 46(3), 229-234.
9. Hu, X., Shen, H., Wang, Y. and Zhao, M. (2017). Liver X receptor agonist TO901317 attenuates paraquat-induced acute lung injury through inhibition of NF- $\kappa$ B and JNK/p38 MAPK signal pathways. *BioMed Research International*, 2017, 13.
10. Huang, C. J., Yang, M. C. and Ueng, S. H. (2005). Subacute pulmonary manifestation in a survivor of severe paraquat intoxication. *The American Journal of the Medical Sciences*, 330(5), 254-256.
11. Junbo, Z., Yongtao, Y., Hongbo, L., Fenshuang, Z., Ruyun, L. and Chun'ai, Y. (2017). Experimental study of sucralfate intervention for paraquat poisoning in rats. *Environmental Toxicology and Pharmacology*, 53, 57-63.
12. Khodayar, M. J., Kiani, M., Hemmati, A. A., Rezaie, A., Zeratifard, M. R., Nooshabadi, M. R. R. and Goudarzi, M. (2014). The preventive effect of atorvastatin on paraquat-induced pulmonary fibrosis in the rats. *Advanced Pharmaceutical Bulletin*, 4(4), 345.
13. Lakshman, M., Sudha, V. and Haripriya, B. (2017). Ultrastructural Pathology of Paraquat (PQ) Induced Acute and Subacute Lung Injury in Experimental Rats. *International Journal Science and Research*, 6(6), 1454-1458.
14. Lalruatfela, P. L., Saminathan, M., Ingole, R. S., Dhama, K. and Joshi, M. V. (2014). Toxicopathology of paraquat herbicide in female wistar rats. *Asian Journal of Animal and Veterinary Advances*, 9(9), 523-542.
15. Mainwaring, G., Lim, F. L., Antrobus, K., Swain, C., Clapp, M., Kimber, I., Orphanides, G. and Moggs, J. G. (2006). Identification of early molecular pathways affected by paraquat in rat lung. *Toxicology*, 225(2-3), 157-72.
16. Reddy, K. A. K. (2019). *Paraquat (PQ) induced ultrastructural and molecular pathology of pulmonary and hepato-renal toxicity in male albino Wistar rats and its amelioration with Vitamin C*. (Master's thesis, P V Narsimha Rao Telangana Veterinary University). Retrieved from <https://krishikosh.egranth.ac.in/handle/1/5810139320>.
17. Reddy, K. B. A. K., Jeevanalatha, M., Lakshman, M. and Rani, M. U. (2019). The Toxic Effects of Paraquat (PQ) on Body Weights and Haematological Parameters in Male Albino Wistar Rats and its Amelioration with Vitamin C. *International Journal of Current Microbiology and Applied Sciences*, 8(11), 314-320.
18. Shahzad, C. M., Mohafez, O. M., Rasool, S. T. and Nair, A. B. (2017). Effect of vitamin C on N, N'-dimethyl-4, 4'-bipyridinium dichloride-induced hepatic and renal toxicity in Swiss albino mice. *Tropical Journal of Pharmaceutical Research*, 16(11), 2645-2649.
19. Sharp, C. W., Ottolenghi, A. and Posner, H. S. (1972). Correlation of paraquat toxicity with tissue concentrations and weight loss of the rat. *Toxicology and Applied Pharmacology*, 22(2), 241-251.
20. Shopova, V. L., Dancheva, V. Y., Salovsky, P. T., Stoyanova, A. M. and Lukanov, T. H. (2007). Protective effect of U-74389G on paraquat induced pneumotoxicity in rats. *Environmental Toxicology and Pharmacology*, 24(2), 167-173.
21. Snedecor, G. W. and Cochran, W. G. (1994). *Statistical Methods. 8th Edn.* Ames, Iowa: Iowa State University Press.

22. Sun, Y., Zhang, J., Yan, Y., Chi, M., Chen, W., Sun, P. and Qin, S. (2011). The protective effect of C-phycocyanin on paraquat-induced acute lung injury in rats. *Environmental Toxicology and Pharmacology*, 32(2), 168-174.
23. Suntres, Z. E. (2002): Role of antioxidants in paraquat toxicity. *Toxicology*, 180(1), 65-77.
24. Tan, D., Wang, Y., Bai, B., Yang, X. and Han, J. (2015). Betanin attenuates oxidative stress and inflammatory reaction in kidney of paraquat-treated rat. *Food and Chemical Toxicology*, 78, 141-146.
25. Yang, Z., Sun, Z., Liu, H., Ren, Y., Shao, D., Zhang, W., Lin, J., Wolfram, J., Wang, F. and Nie, S. (2015). Connective tissue growth factor stimulates the proliferation, migration and differentiation of lung fibroblasts during paraquat-induced pulmonary fibrosis. *Molecular Medicine Reports*, 12(1), 1091-1097.

\*\*\*\*\*