

Gross Morphological and Morphometrical Studies on the Hyoid Apparatus of Adult Broiler Chicken (*Gallus domesticus*)

Srinivas Sathapathy^{1*}, Santosh Kumar Sahu¹, Shuvranshu Shekhar Biswal², Suman Kumari Joshi³ and Imran Ali⁴

¹Department of Veterinary Anatomy and Histology, CVSc. and A.H., OUAT, Bhubaneswar – 751 003, Odisha, INDIA

²Department of ARGO, TVCC, CVSc. and Animal Husbandry, OUAT, Bhubaneswar – 751 003, Odisha, INDIA

³Scientist (Animal Science), KVK, Jharsuguda, OUAT, Bhubaneswar – 751 003, Odisha, INDIA

⁴Department of Veterinary Pathology, Bihar Veterinary College, BASU, Patna – 800 014, Bihar, INDIA

*Corresponding Author: srinivas.ouat@gmail.com

How to cite this paper:

Sathapathy, S., Sahu, S., Biswal, S., Joshi, S., & Ali, I. (2020). Gross Morphological and Morphometrical Studies on the Hyoid Apparatus of Adult Broiler Chicken (*Gallus domesticus*). *International Journal of Livestock Research*, 10(7), 139-142. doi:

<http://dx.doi.org/10.5455/ijlr.20200514125220>

Received : May 14, 2020
Accepted : Jun 21, 2020
Published : Jul 31, 2020

Copyright © Sathapathy *et al.*, 2020

This work is licensed under the Creative Commons Attribution International License (CC BY 4.0). <http://creativecommons.org/licenses/by/4.0/>



Abstract

The present gross morphological and morphometrical study was conducted on the hyoid apparatus of healthy adult broiler chicken. It was found that the hyoid apparatus consisted of basihyal bone, urohyal bone and two rami. Further, the two rami consisted of bony and cartilaginous parts. The biometrical measurements were taken from the various segments of hyoid apparatus. The basihyal bone and urohyal bones were of similar length. The thickness of basihyal bone increased from cranial to caudal aspect, but the width of urohyal bone followed decreasing trend towards the caudal aspect. The left ceratobranchiale was comparatively wider than the right one. The distance between the two ceratobranchiales followed a regular decrease towards the caudal aspect. The width and thickness were almost equal in both the ceratobranchiales, but the width gradually decreased towards the caudal aspect in both the epibranchiales. Both the epibranchiales were of equal thickness and gradually became thinner towards the caudal aspect in both the epibranchiales. The biometrical observation in the present study would contribute a baseline data on the hyoid apparatus of adult broiler chicken which could be useful for future research.

Keywords: Chicken, Hyoid Apparatus, Morphology, Morphometry

Introduction

Birds have unique features that help them with the adaptations for life style, transporting, selecting or rejecting, and manipulating the food towards the gullet. The jaw apparatus, laryngeal apparatus and lingual apparatus are vital components of the feeding apparatus in birds (Nefei, 2017). The shape and size of the hyoid apparatus influence the shape and function of the tongue. Long hyoid bones help the tongue to protrude well outside the mouth cavity. The hyoid apparatus in birds consists of the tongue bones along with associated connective tissues, cartilage, and soft tissues such as muscles, dermis and epidermis (Jung *et al.*, 2016). The primary function of the hyoid apparatus is to anchor and allow for the extension of the tongue (Homberger and Meyers, 1989). In most birds, the hyoid apparatus consists of five distinct bones: the paraglossal, basihyal, urohyal, paired ceratobranchial and paired epibranchial. Between the different bones, there are joints that provide for the movement required during feeding. The hyoid apparatus has the potential ability to withstand impact and aid the skull in avoiding brain injuries (Nag *et al.*, 2007 and Zhou *et al.*, 2009) by lowering the compressive and tensile stresses in the brain up to 40% during pecking (Oda *et al.*, 2006). The hyoid bone was also suggested to play the role of a 'seat belt' after impact (Wang *et al.*, 2011). In addition, the function of the hyoid bone was computationally assessed by Liu *et al.* (2015) who found that there was 30% less deformation of the whole head with the hyoid bones than without them and they concluded that the hyoid bone and associated muscles contributed together to increase the rigidity of the whole head, reducing the deformation and oscillation of the skull. The present study was planned to develop a baseline data on the morphology and morphometry of hyoid apparatus in adult broiler chicken because of the scarcity of the available literature.

Materials and Methods

Six heads from healthy adult broiler chickens were collected from the local market (chicken shop) of Bhubaneswar, Odisha. All the heads were separated at the level of the second cervical vertebra. The hyoid apparatus was dissected out carefully for gross and biometrical study. The measurements such as weight, length, width (cranial, middle and caudal), thickness of basihyal bone, urohyal bone, two bony ceratobranchiales and cartilaginous epibranchiales, etc. were carried out on the segments of hyoid apparatus with the help of digital weighing balance (for weight), scale, thread and digital Vernier's calliper (for length, width and thickness).

Results and Discussion

The hyoid apparatus was situated between the rami of the mandible for providing support to the root of the tongue, larynx and pharynx in the adult broiler chicken similar to the description of Sisson and Grossman (1975), but in contrary to the reports of Jung *et al.* (2016) who found the structure of the hyoid apparatus in a golden-fronted woodpecker (*Melanerpes aurifrons*) was elongated and wrapped around the skull from the rostral (toward the beak) to the caudal (toward the terminal end).

Gross Morphology

The hyoid bone in chicken consisted of an unpaired basihyal bone, paired hyoid rami and an urohyal bone which was similar to the description of Sisson and Grossman (1975) and Nickel *et al.* (1977) in chicken, but contradictory to the finding of Jung *et al.* (2016) who reported the absence of urohyal bone in Woodpecker. The basihyal bone was unpaired, short, flat, rod-like and cartilaginous, wherein its rostral and caudal extremities were relatively wide and compressed laterally. The present observation was in agreement with the findings of Tadjalli *et al.* (2008) in ostrich. It articulated caudally with urohyal bone in a synarthrosis and on each side of its caudo-lateral aspect there were articular surfaces for the hyoid rami. The urohyal bone was a rod-like cartilaginous process that supports adjacent tissues, larynx, cartilage, ligament and muscles (Homberger and Meyers, 1989). The rami of hyoid bone lied laterally and each hyoid ramus consisted of ceratobranchiale which joints with the basihyal bone rostrally, and a curved epibranchiale that formed the terminal segment (Fig. 1).

Gross Morphometry

The average weight of the hyoid apparatus of adult broiler chicken was recorded to be 0.55 ± 0.006 gm.

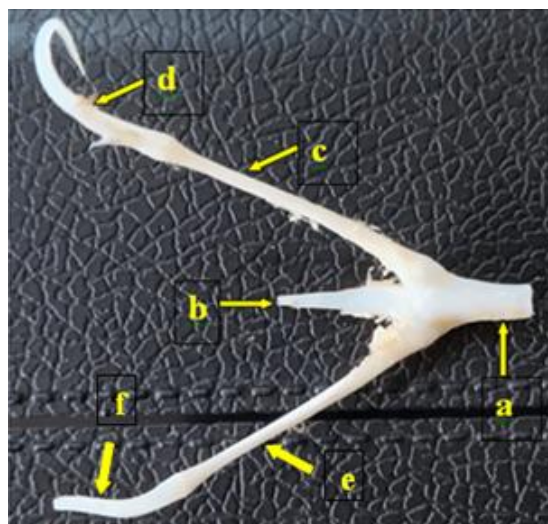


Figure 1: Dorsal view of hyoid apparatus of adult chicken showing-a) Basihyal; b) Urohyal bone; c) Right bony ramus; d) Right cartilaginous ramus; e) Left bony ramus; f) Left cartilaginous ramus

Basihyal Bone

The average length of basihyal bone was found to be 1.1 ± 0.08 cm. The average width of basihyal bone at the cranial, middle and caudal aspects was recorded as 0.3 ± 0.001 cm, 0.5 ± 0.004 cm and 0.7 ± 0.002 cm respectively. Similarly, the average thickness of basihyal bone at the cranial, middle and caudal aspects was recorded as 0.2 ± 0.001 cm, 0.3 ± 0.001 cm and 0.4 ± 0.002 cm respectively.

Urohyal Bone

The average length of urohyal bone was found to be 1.1 ± 0.06 cm. The average width of urohyal bone at the cranial, middle and caudal aspects was recorded as 0.3 ± 0.002 cm, 0.2 ± 0.001 cm and 0.1 ± 0.001 cm respectively. Similarly, the average thickness of urohyal bone at the cranial, middle and caudal aspects was recorded as 0.2 ± 0.002 cm, 0.1 ± 0.001 cm and 0.06 ± 0.002 cm respectively.

Ceratobranchiales

The average length of left ceratobranchiale was found to be 2.7 ± 0.11 cm. The average width of left ceratobranchiale at the cranial, middle and caudal aspects was recorded as 0.3 ± 0.002 cm, 0.2 ± 0.001 cm and 0.2 ± 0.004 cm respectively. Similarly, the average thickness of left ceratobranchiale at the cranial, middle and caudal aspects was recorded as 0.2 ± 0.001 cm, 0.1 ± 0.001 cm and 0.1 ± 0.002 cm respectively. The average length of right ceratobranchiale was found to be 2.5 ± 0.12 cm. The average width of right ceratobranchiale at the cranial, middle and caudal aspects was recorded as 0.2 ± 0.001 cm, 0.1 ± 0.001 cm and 0.1 ± 0.001 cm respectively. Similarly, the average thickness of right ceratobranchiale at the cranial, middle and caudal aspects was recorded as 0.2 ± 0.002 cm, 0.1 ± 0.001 cm and 0.1 ± 0.002 cm respectively. Further, the average distance between the two ceratobranchiales was measured as 2.8 ± 0.13 cm, 1.9 ± 0.09 cm and 1.1 ± 0.10 cm at the cranial, middle and caudal aspects respectively.

Epibranchiales

The average length of left epibranchiale was found to be 1.6 ± 0.07 cm. The average width of left epibranchiale at the cranial, middle and caudal aspects was recorded as 0.2 ± 0.001 cm, 0.1 ± 0.001 cm and 0.07 ± 0.004 cm respectively. Similarly, the average thickness of left epibranchiale at the cranial, middle and caudal aspects was recorded as 0.2 ± 0.002 cm, 0.1 ± 0.001 cm and 0.05 ± 0.002 cm respectively. The average length of right epibranchiale was found to be 1.1 ± 0.06 cm. The average width of right epibranchiale at the cranial, middle and caudal aspects was recorded as 0.2 ± 0.001 cm, 0.1 ± 0.001 cm and 0.03 ± 0.002 cm respectively. Similarly, the average thickness of right epibranchiale at the cranial, middle and caudal aspects was recorded as 0.2 ± 0.001 cm, 0.1 ± 0.001 cm and 0.05 ± 0.002 cm respectively. Further, the average distance between the two epibranchiales was measured as 3.1 ± 0.16 cm, 3.2 ± 0.14 cm and 2.8 ± 0.08 cm at the cranial, middle and caudal aspects respectively.

Conclusion

From the present study, it can be concluded that the left ceratobranchiale and left epibranchiale were longer than their right counterparts. Both the ceratobranchiales were of same thickness. The two epibranchiales were more apart from each other than the ceratobranchiales. The left ceratobranchiale was comparatively wider and thicker than the right one, whereas the left epibranchiale was wider only at the caudal aspect than the right epibranchiale. Further, the various parameters of hyoid apparatus of adult broiler chicken such as length, cranial, middle and caudal width, thickness of basihyal bone, urohyal bone, two bony and epibranchiales showed characteristic biometric differences, which would help to develop a baseline data in this species.

Conflict of Interests

There is no conflict of interest.

Publisher Disclaimer

IJLR remains neutral concerning jurisdictional claims in published institutional affiliation.

References

1. Fatma A. Al-Nefei. (2017). Kinetics of the Hyoid Skeleton of the Rock Dove (*Patagioenas livia*). *Int. J. Adv. Res. Bio. Sci.* 4(10), 51-61.
2. Homberger, D.G. and Meyers, R.A. (1989). Morphology of the lingual apparatus of the domestic chicken (*Gallus gallus*) with special attention to the structure of the fasciae. *Am. J. Anat.* 186, 217–257.
3. Jung, J.Y., Steven E. Naleway, Nicholas A. Yaraghi, Steven Herrera, Vincent R. Sherman, Eric A. Bushong, Mark H. Ellisman, David Kisailus, Joanna McKittrick. (2016). Structural analysis of the tongue and hyoid apparatus in a woodpecker. *Acta Biomaterialia*. 37, 1–13.
4. Liu, Y., Qiu, X., Zhang, X. and Yu, T. X. (2015). Response of woodpecker's head during pecking process simulated by material point method. *PLoS One* 10, e0122677.
5. Nag, S., Banerjee, R. and Fraser, H.L. (2007). A novel combinatorial approach for understanding microstructural evolution and its relationship to mechanical properties in metallic biomaterials. *Acta Biomater.* 3, 369–376.
6. Nickel, R., Schummer, A., Seiferle, E. (1977). Anatomy of the domestic birds (2nd Edn.), Vol. 5, Verlag paul parey, Berlin and Hamburg, pp. 25-64.
7. Oda, J., Sakamoto, J. and Sakano, K. (2006). Mechanical evaluation of the skeletal structure and tissue of the woodpecker and its shock absorbing system. *J. Soc. Mech. Eng. Int. J. Ser. A: Solid Mech. Mater. Eng.* 49, 390–396.
8. Sisson and Grossman (1975). Anatomy of the domestic animal (5th Edn.), WB Saunders, Philadelphia, USA.
9. Tadjalli, M., Mansouri, S. H. and Poostpasand, A. (2008). Gross anatomy of the oropharyngeal cavity in the ostrich (*Struthio camelus*). *Iranian J. Vet. Res.* 9(4), 316-323.
10. Wang, L., Cheung, J.T.M., Pu, F., Li, D., Zhang, M. and Fan, Y. (2011). Why do woodpeckers resist head impact injury: A biomechanical Investigation. *PLoS One* 6, e26490.
11. Zhou, P., Kong, X. Q., Wu, C. W. and Chen, Z. (2009). The novel mechanical property of tongue of a woodpecker. *J. Bionic Eng.* 6, 214–218.
