



Morphological and Morphometrical Studies on the Sternum of Chinese Goose (*Anser cygnoides*)

O. R. Sathyamoorthy^{1*}, R. Richard Chruchil², K. Sangilimadan³ and S. Dhamotharan³

¹Department of Veterinary Anatomy, Madras Veterinary College, Tamil Nadu Veterinary and Animal Sciences University, Chennai-7, Tamil Nadu, INDIA

²Poultry Research Station, Madhavaram Milk Colony, TANUVAS, Chennai -51, Tamil Nadu, INDIA

³Department of Poultry Science, Madras Veterinary College, Tamil Nadu Veterinary and Animal Sciences University, Chennai-7, Tamil Nadu, INDIA

*Corresponding Author: drsathya1971@gmail.com

How to cite this paper:

Sathyamoorthy, O., Richard, C., Sangilimadan, K., & Dhamotharan, S. (2020). Morphological and Morphometrical Studies on the Sternum of Chinese Goose (*Anser cygnoides*). *International Journal of Livestock Research*, 10(7), 143-149. doi: <http://dx.doi.org/10.5455/ijlr.20200324020559>

Received : Mar 24, 2020
Accepted : Jun 14, 2020
Published : Jul 31, 2020

Copyright © Sathyamoorthy *et al.*, 2020

This work is licensed under the Creative Commons Attribution International License (CC BY 4.0). <http://creativecommons.org/licenses/by/4.0/>



Abstract

The sternum of Anser cygnoides consisted of a manubrium sterni, a corpus sterni and a sternal crest. The manubrium sterni is very small, flat and extended only from the middle of the ventral lip of the cranial border. The corpus sterni is large, quadrilateral, broad in the cranial two thirds and narrow in the caudal one third. The dorsal surface showed numerous pneumatic foraminae. An elongated deep transverse articular groove is seen in cranial border. The craniolateral processes are thin, short and broad. Seven articular cylinders and the troughs between them containing large pneumatic foraminae are seen at the lateral borders. The processes thoracicus was absent. The caudolateral processes extended beyond the caudal border of the sternum and enclosed along with the lateral border of the corpus sterni, the incisura ovalis. The sternal crest was prominent, projected from below the sternal spine, and ended before the caudal border.

Keywords: Caudolateral Process, Corpus Sterni, Craniolateral Process, Sternal Crest, Sternal Spine

Introduction

Chinese geese are considered by many to be the most graceful and beautiful member of the goose family. They are also referred to as ‘swan geese’ or ‘weeder geese’. The sternum is a large unsegmented bone, which with its processes forms a considerable part of the ventral body wall. It gives attachment to the large flight muscles (Dyce *et al.*, 2010). The present study was undertaken to study the anatomy of sternum of Chinese goose, the information of which is scanty in the literature.

Materials and Methods

The carcass of three Chinese geese were utilised for the present study. The dead Chinese geese aged between 70 to 80 weeks of age were subjected for this study. After the post-mortem examination the carcasses, the skin of the birds along with feathers was removed completely. The skin of geese can be separated from the body by careful flaying as the carcass is attached firmly with the skin in many localized areas in geese compared to other birds. The abdominal cavity was opened carefully to remove the viscera and other soft organs. The muscles close to their attachment to the bones and cartilages were separated without damaging cartilages and the joints were separated. Then the carcasses were allowed for biological maceration by maggots. The disintegrated skeleton was cleaned with fresh water and soaked in 10 to 15% NaHCO₃ solution for whitening. The bones were then dried and morphological and morphometric studies were recorded with the help of Vernier calipers and ruler.

Results and Discussion

The sternum of Chinese goose (*Anser cygnoides*) consisted of a manubrium sterni or sternal spine, a corpus sterni or body (Fig. 1) and a sternal crest or keel (Fig. 2).

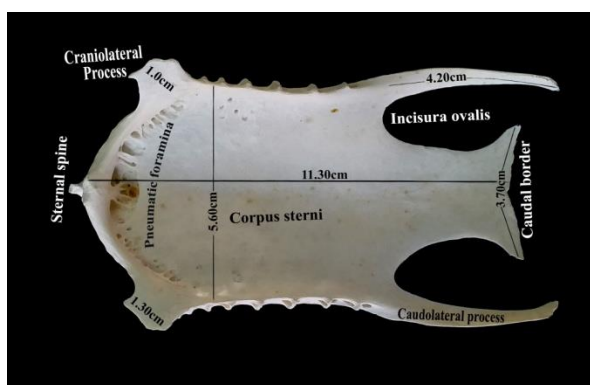


Figure 1: Sternum of Chinese goose (Dorsal view)

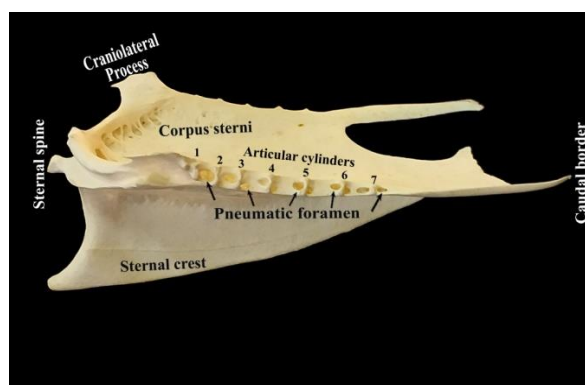


Figure 2: Sternum of Chinese goose (Lateral view)

The manubrium sterni was very small (3mm), flattened from side to side and cranially projected structure. It extended only from the middle of the ventral lip of the cranial border (Fig. 2). Similarly, in spot-billed pelicans (Sathyamoorthy *et al.*, 2012), pigeon hawk (John *et al.*, 2014a), common moorhen (Wani *et al.*, 2017) and in blue and yellow macaw (Sathyamoorthy *et al.*, 2019) it arose only from the ventral edge of the cranial border. The sternal spine was thick and triangular process in spot-billed pelicans, a pointed process in pigeon hawk whereas in blue and yellow macaw it was thick, upwardly bent spine-like process (Sathyamoorthy *et al.*, 2019). In common myna, Himalayan bulbul and house sparrow, the sternal spine was ‘Y’ shaped and fused with the cranial end of the keel and placed roughly at an angle of 30° against the cranial end of the body (John *et al.*, 2017). The sternal spine was ‘Y’ shaped in crow and highly reduced in owl (John *et al.*, 2014b) and smaller in crested serpent eagle (Choudhary *et al.*, 2018). In fowl, the sternal spine arose as two processes from the dorsal and ventral edges of the groove which fused into a median vertical bony plate, leaving an opening between them. In pigeon, the two processes remained separate, while in duck and goose only the ventral process was present. From the sternal spine the membrane sternocoracoclavicularis originated and hold the sternum, coracoid and clavicle together (Nickel *et al.*, 1977). In turkey and peacock the sternal spine was similar in structure to fowl, whereas in duck and white breasted water hen, only the ventral process was present as a pointed projection (Pathak *et al.*, 2017). In contrary, the sternal spine was absent in ostrich (Sathyamoorthy and Ramesh, 2006), in emu (Jagapathi *et al.*, 2007) and in pariah kite (Tomar *et al.*, 2011).

The corpus sterni was large, quadrilateral in shape and 11.3cm long. The width of the cranial border between the lateral borders of the craniolateral process was 6.75cm, between the medial borders of craniolateral process the width was 5.0cm, behind the craniolateral process the width was 5.60cm. The caudal border was 3.70cm wide. The cranial two thirds of the corpus sterni was broad and their lateral borders were thick and straight, whereas in the caudal one third the corpus sterni was quadrilateral, narrow, with sharp, thin and concave borders. At the caudal end it projected laterally into a triangular process (Fig.1). It is in accordance with the observations of John *et al.* (2014b) who reported that the width of the sternum at anterior aspect was more than the posterior aspect in pigeon and crow, whereas in owl the width at the both ends was approximately equal. In pigeon hawk the sternal body was roughly rectangular, the cranial end was narrow and the caudal end was wide (John *et al.*, 2014a).

In case of chicken the sternum was relatively long and narrow (Dyce *et al.*, 2010). In ostrich (Sathyamoorthy and Ramesh, 2006) and emu (Jagapathi *et al.*, 2007), the sternum was a large bowl-shaped bone. Jayachitra *et al.* (2015) reported that in duck the sternum was rectangular with very shallow dorsal surface. Wani *et al.* (2017) reported that in common moorhen the anterior half of the sternal body was quadrilateral whereas the posterior half was triangular. Pathak *et al.* (2017) reported that, in peacock and turkey the cranial part of the corpus sterni was quadrilateral and strongly concave plate of bone. The caudal part of corpus sterni was long, shallow, gradually became narrow and terminated into a blunt pointed end in peacock, whereas in turkey it was long, narrow cranially and wide caudally and terminated into a rounded end. In duck the corpus sterni was rectangular in shape (Jayachitra *et al.*, 2015), but in white-breasted waterhen the cranial part of the corpus sterni was rectangular and behind the level of caudolateral process it was triangular in shape (Pathak *et al.*, 2017).

In the present study, the dorsal surface of the corpus sterni was less concave and showed a shallow wide groove in the centre extending from behind the cranial border to caudal border. The concavity was more in the cranial half and less in the caudal half. At the level of the origin of the caudolateral process it showed a slight convexity (Fig.1). It is in accordance with the observations of John *et al.* (2014b) in pigeon who observed that the dorsal surface was concave in the anterior two-third portion only whereas the remaining surface was almost flat. In owl, the concavity was more as compared to pigeon and crow. The dorsal surface was also concave in bald ibis (Dursun *et al.*, 2002), ostrich (Predoi *et al.*, 2009), pariah kite (Tomar *et al.*, 2011), spot-billed pelican (Sathyamoorthy *et al.*, 2012), pigeon hawk (John *et al.*, 2014a), myna, Himalayan bulbul and house sparrow (John *et al.*, 2017) and blue and yellow macaw (Sathyamoorthy *et al.*, 2019).

The dorsal surface showed numerous pneumatic foraminae behind the cranial border up to the level of craniolateral processes. On the dorsal surface, the middle of the cranial border showed a prominent bony ridge. Largest foramina were observed in either side of ridge. From the base of the ridge another large foramina extended deep in to the cranial border of the sternal crest (Fig.1). Behind the craniolateral processes also two to three small foraminae were noticed. Nickel *et al.* (1977) reported that, in chicken behind the cranial border several small pneumatic foramina and a strikingly large median pneumatic foramen were present. Dursun *et al.* (2002) observed 15 to 20 pneumatic pores on the visceral surface of sternum in bald ibis. Pneumatic foramina communicate with clavicular air sac and help to lower the wing load without loss of strength. John *et al.* (2014b) observed that, in pigeon the pneumatic foramen was single and median whereas, in crow and owl additional foramina were present on either side of median one. John *et al.* (2014a) also observed that in pigeon hawk just caudal to the cranial border a well-developed median pneumatic foramen and a number of small lateral pneumatic foraminae on either side of median pneumatic foramen and also additional foraminae in the middle of the median line of the dorsal surface. Jayachitra *et al.* (2015) reported that in turkey and duck the dorsal surface of the body was pierced by numerous small foramina. Wani *et al.* (2017) observed that, in common moorhen the median groove at cranial end presented an elongated median pneumatic foramen, and it communicated with the ventral surface of the body. Sathyamoorthy *et al.* (2019) observed that, in blue and yellow macaw numerous small pneumatic foraminae were present on the dorsal surface of the body in the cranial half behind the cranial and craniolateral borders, in the midline, and large median foramina behind the cranial border. In contrary, Jagapathi *et al.* (2007) and Jayachitra *et al.* (2015) informed that, in emu the pneumatic foramen was not present on the dorsal surface.

In the present study, the cranial border was 5.0cm wide between the medial borders of craniolateral processes and 6.75cm wide between the lateral borders of the craniolateral processes, thick (1.2 cm in the centre), semicircular and showed dorsal and ventral ridges. Between the dorsal and ventral ridges the cranial border showed an elongated deep transverse articular groove with a faint ridge in the centre, for the coracoids bones (Fig. 3). However, the cranial border was triangular in pariah kite (Tomar *et al.*, 2011) and in peacock and turkey (Pathak *et al.*, 2017). In

fowl, duck, goose and pigeon (Nickel *et al.*, 1977), and in crested serpent eagle (Choudhary *et al.*, 2018), cranial border presented a deep groove on either side to receive the cylindrical distal ends of the coracoid bone.

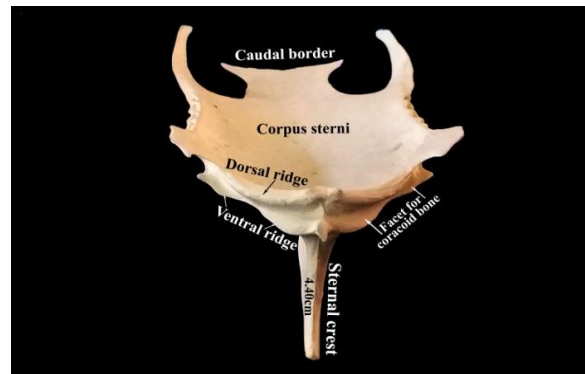


Figure 3: Sternum of Chinese goose (Cranial view)

The dorsal ridge was thick and showed a transverse notch in the centre bounded by small bony projections on either side (Fig.3). Similarly, John *et al.* (2014b) in crow and owl and Wani *et al.* (2017) in common moorhen reported that, the dorsal lip presented a central notch. The ventral ridge was thin, sharp, showed the sternal spine in the middle and at either extremity it became prominent and showed a plate-like projection. In ostrich (Predoi *et al.*, 2009) and in pigeon, crow and owl (John *et al.*, 2014b) the groove on the cranial border presented facets for coracoids and the groove was limited by two unequal lips.

The craniolateral angle showed the craniolateral processes on either side. The craniolateral processes were 1.0cm tall and 1.30cm wide. They were thin, short, wide, projected laterally and slightly cranially (Fig. 1). Nickel *et al.* (1977) reported that, this process was very large in the fowl, very short in the pigeon and small in duck and goose. In emu, the craniolateral process was short, wide, convex and rough ventrally, and projected dorsolaterally (Jagapathi *et al.*, 2007), and in ostrich it was well developed (Predoi *et al.*, 2009). The craniolateral processes were prominent in owl, less developed in crow and least developed in pigeon (John *et al.*, 2014b), short in pigeon hawk (John *et al.*, 2014a), highly developed in mynah, and moderately developed in Himalayan bulbul and least in-house sparrow (John *et al.*, 2017). In peacock, turkey, duck and white-breasted water hen the craniolateral processes were craniolaterally directed. This processes were hamulus shaped and did not extend up to the sternal spine in peacock, dagger shaped and extended beyond the tip of sternal spine in turkey, hook shaped and did not extend beyond the sternal spine in duck and in waterhen it was large, triangular shaped and extended up to the base of the sternal spine (Pathak *et al.*, 2017). In common moorhen the craniolateral processes were moderately developed and projected craniolaterally (Wani *et al.*, 2017). In pariah kite the craniolateral processes were absent (Tomar *et al.*, 2011).

In the present study, the lateral borders behind the craniolateral processes were thick cranially and thin caudally, straight and showed seven articular cylinders for the sternal ribs. The troughs between the articular areas showed large pneumatic foraminae (Fig. 2). Nickel *et al.* (1977) informed that the number of articular cylinders corresponded to the number of sternal ribs and the troughs between the articular cylinders contained the pneumatic foraminae. The numbers of articular cylinders were three pairs in rhea (Brett and Hopkins, 1991), four pairs in emu and turkey (Jayachitra *et al.*, 2015), peacock and turkey (Pathak *et al.*, 2017) and house sparrow (John *et al.*, 2017), five pairs in ostrich (Brett and Hopkins, 1991), spot-billed pelicans (Sathyamoorthy *et al.*, 2012), pigeon hawk (John *et al.*, 2014a), mynah and Himalayan bulbul (John *et al.*, 2017) and blue and yellow macaw (Sathyamoorthy *et al.*, 2019), seven pairs in ducks (Jayachitra *et al.*, 2015), and also seven pairs without pneumatic foraminae in white-breasted waterhen (Pathak *et al.*, 2017). The processes thoracicus is absent in the Chinese goose. Similarly, it is also absent in emu (Jagapathi *et al.*, 2007), pariah kite (Tomar *et al.*, 2011), crow and owl (John *et al.*, 2014b), duck and white-breasted water hen (Pathak *et al.*, 2017), and blue and yellow macaw (Sathyamoorthy *et al.*, 2019). It arose independently in pigeon, but with the caudolateral process in peacock and turkey (Pathak *et al.*, 2017). Behind this, the lateral borders were continued by the caudolateral processes in Chinese goose. The caudolateral processes were 4.20cm long and extended slightly beyond the caudal border of the sternum. The caudolateral processes were wide, thick and pneumatized in the beginning and became narrow, gradually thin and ended in a medially bent pointed tip. It enclosed along with the lateral border of the corpus sterni an oval incisure (Fig. 1). Dursun *et al.* (2002) reported that in bald ibis the caudal border showed a strong caudolateral process laterally, in addition the caudal border also showed an intermediate processes on both sides and a median process in the centre. Similarly, in brown

wood owl also the caudal border showed a very long caudolateral processes laterally and two small intermediate processes medially on either side of the metasternum (Choudhary *et al.*, 2018).

In spot-billed pelicans the caudolateral processes were short and caudally directed (Sathyamoorthy *et al.*, 2012). The caudolateral processes were single in crow and owl. It was least developed in owl and also incisura ovalis was not noticed. In crow it was directed backwards and upwards. In pigeon caudolateral processes and processes thoracicus were present and the caudolateral processes were directed backwards (John *et al.*, 2014b). In common moorhen the caudolateral processes were long, thin and terminated well behind the caudal end of the sternal body (Wani *et al.*, 2017). Pathak *et al.* (2017) observed the caudolateral processes in all the four species studied *viz.*, peacock, turkey, duck and white-breasted waterhen. In peacock and turkey it was long, narrow, widened out in its terminal part and ran more or less parallel with the corpus sterni as in fowl. In duck and white-breasted waterhen, the processes were clasp like. In peacock, turkey and duck it did not extend beyond the caudal end of the sternum, but in white-breasted waterhen it extended beyond the caudal end of the sternum and also ran parallel with the corpus sterni. The caudolateral processes and the incisura ovalis were absent in emu (Jagapathi *et al.*, 2007) and in pariah kite (Tomar *et al.*, 2011).

The caudal border of the corpus sterni was wide measuring 3.7cm. It was notched in the centre and convex on either side. On lateral aspect, it prolonged into a pointed process forming incisura ovalis on either side (Fig.1). The caudal border present notches in fowl, duck and goose (Nickel *et al.*, 1977), crow (John *et al.*, 2014b), and in peacock, turkey, duck and white-breasted water hen (Pathak *et al.*, 2017). Dursun *et al.* (2002) observed that in bald ibis the caudal border was zigzag and showed three eminent processes, the lateral caudolateral processes, intermediate processes and a medial processes. The medial process was strongest one and located in the centre. The caudal border showed totally four incisures, two on either side. In barn wood owl also the caudal border showed four incisures (Choudhary *et al.*, 2018). In pigeon hawk, the caudal border was concave in the middle part and convex on the lateral parts but the incisura ovalis was absent (John *et al.*, 2014a).

The ventral surface of the corpus sterni was less convex, smooth and showed the sternal crest in the centre (Fig. 4). It is in accordance with the observations of the Nickel *et al.* (1977) in fowl, pigeon, duck and goose. In the present study the ventral surface also showed a thin, sharp ridge starting from the ventral surface of the ventral ridge of the cranial border of the sternum and extended up to the lateral border of the caudal free part of the corpus sterni. It ran parallel to the lateral border of the corpus sterni and prominent cranially and became less prominent caudally. It is in accordance with the observations of Sathyamoorthy *et al.* (2019) in blue and yellow macaw.

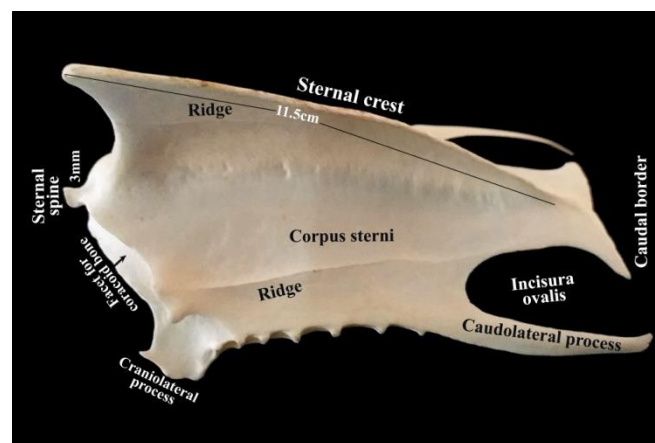


Fig-4: Sternum of Chinese goose-Ventrolateral view

The sternal crest was prominent, triangular in shape and 11.50 cm long. Its cranial border was 3.20cm height. Height of the sternal crest along with the cranial border was 4.40cm. It projected from below the sternal spine, formed a caudally directed arch, gradually reduced in height and ended before the caudal border (Fig.4). Similarly, John *et al.* (2014a) observed that in pigeon hawk, the sternal crest was triangular, the base of the crest was straight, thick and in line with the cranial border, but terminated well before the caudal border. Its cranial border was thick, pneumatized and straight above & concave below. Cranioventrally it projected as a triangular projection, and extended beyond the level of the sternal spine and formed the cranial most structure of the sternum. Its ventral

border was thick and convex in the cranial half and thin caudally and ended well before the caudal border of the sternum. Its lateral surface showed a sharp ridge above the ventral border which extended from the middle of the cranial border up to the caudal one third (Fig.2). Nickel *et al.* (1977) observed that, the sharp cranial end of the crest is concave in fowls and pigeons but straight in duck and goose. It does not extend to the cranial border of the sternum in the fowl. It's slightly thickened ventral border is somewhat concave in the fowl, duck and goose.

In spot - billed pelicans the sternal crest was triangular, small and extended only up to the cranial half. Its cranial border was straight, sharp and extended beyond the cranial border of the sternum. The clavicle was fused to the cranial border of the sternal crest permanently (Sathyamoorthy *et al.*, 2012). In common moorhen (Wani *et al.*, 2017) and in peacock, turkey and white-breasted water hen (Pathak *et al.*, 2017) the sharp cranial end of the crest was concave and did not reach to the cranial border of the sternum. In common myna, Himalayam bulbul and house sparrow the keel was highly developed triangular structure. In mynah and sparrow the tip of the base is in level with the rostrum, whereas in bulbul it was just in front of the cranial end of the sternal body (John *et al.*, 2017). In blue and yellow macaw the cranial border of the sternal crest was concave and thin above and convex and thick below. The cranial border of the sternal crest was the cranial most structure of the sternum. The lateral surfaces of the sternal crest and the convex ventral surface of the sternal body presented a sharp ridge extending from the cranial border to the caudal border. These ridges and roughened surfaces give better anchorage to the flight muscles (Sathyamoorthy *et al.*, 2019).

Conclusion

In Chinese goose the manubrium sterni was very small. The corpus sterni was large, quadrilateral and broad. The dorsal surface was less concave and the ventral surface was less convex. It is highly pneumatized and showed pneumatic foraminae on the dorsal surface and on the lateral borders. The cranial border was thick, semicircular, and showed an elongated deep transverse articular groove with a faint ridge in the centre, for the coracoid bone bounded by dorsal and ventral ridges. The craniolateral processes were thin, short and broad. The caudolateral processes were long, thick, pneumatized and slightly extended beyond the caudal border of the sternum and enclosed along with the lateral border of the corpus sterni, the incisura ovalis, which was closed in life by membranes. The caudal border of the body was broad. The sternal crest was prominent, projected from below the sternal spine, and ended before the caudal border. But its surface area was less when compared to the walking birds. Therefore, it can be concluded that the morphology and morphometry of the sternum which is suitable for swimming.

Acknowledgement

The authors are thankful to the Dean, Madras Veterinary College, Chennai and The Professor and Head, Poultry Research Station, Madhavaram Milk Colony, TANUVAS, Chennai-51.

Conflict of Interests

There is no conflict of interest.

Publisher Disclaimer

IJLR remains neutral concerning jurisdictional claims in published institutional affiliation.

References

1. Brett, A. and Hopkins, M.S. (1991). Anatomy of Ostriches, Emus and Rheas. In: *The Ratite Encyclopedia*, 1st edn., Columbia, USA, pp 32-36.
2. Choudhary, O. P., Kalita, P. C., Rajkhowa, T. K., Arya, R. S., Kalita, A. and Doley, P. J. (2018). Gross morphological studies on the sternum of crested serpent eagle (*Spilornis cheela*). *Indian Journal of Animal Research*, 53:1459-1461.
3. Dursun, N., Duzler, A., Bozkurt, E. and Ozgel, O. (2002). Macroanatomical investigations on sternum of bald ibis (*Geronticus eremita*). *Indian Veterinary Journal*, 79:160-165.
4. Dyce, K. M., Sack, W. O. and Wensing, C. J. G. (2010). Text book of Veterinary Anatomy. Edition 4 edition, Saunders Elsevier, St. Louis, Missouri, pp. 784-813.

5. Jagapathi, R. P., Rao, T. S. C., Shanti, L. M. and Reddy, Y. R. (2007). Gross anatomical studies on the sternum and ribs of emu (*Dromaius novaehollandiae*). *Indian Journal of Poultry Science*, 42:112-114.
6. Jayachitra, S., Balasundaram, K. and Paramasivan, S. (2015). Comparative gross anatomical studies on the sternum of emu, turkey and duck. *Indian Journal Veterinary Anatomy*, 27 (1): 61-62.
7. John, M. A., Mamde, C. S., Baba, O. K. and Rohankar, R. U. (2014a). Anatomical studies on sternum of pigeon hawk (*Falco columbarius*). *Indian Journal of Poultry Science*, 49 (2): 231-233.
8. John, M. A., Sasan, J. S., Ahmed, K., Tomar, M. P. S., Ahmad, A. and Singh, A. D. (2014b). Morphometry of sternum of pigeon, crow and owl. *Indian Veterinary Journal*, 91(03): 40-41.
9. John, M. A., Khan, M., Quadir, A., Choudhary, A. R., Baba, M. A., Dar, F. A. and Rafiq, A. (2017). Sternal morphometry of common myna (*Acridotheres tristis*), Himalayan bulbul (*Pyconotus leucogenys*) and house sparrow (*Passer domesticus*). *Applied Biological Research*, 19 (1): 237-240.
10. Nickel, R., Schummer, A. and Seiferle, E. (1977). *Anatomy of the Domestic Birds*. Verlag Paul Parey, Berlin, Hamburg, pp. 10-12.
11. Pathak, A., Gupta, S. K., Verma, A., Farooqui, M. M., Prakash, A. and Kumar, P. (2017). Comparative gross anatomy of the sternum in peacock (*Pavo cristatus*), turkey (*Meleagris gallopavo*), duck (*Anas platyrhynchos*) and white-breasted water hen (*Amaurornis phoenicurus*). *Journal of Animal Research*, 7 (3):501-505.
12. Predoi, G., Belu, I., Georgescu, B., Seicaru, A., Rosu, P., Carmen, B. and Dumitrescu, F. (2009). Comparative researches regarding the sternum in ostrich (*Struthio camelus*) and nandu (*Rhea Americana*). *Lucrari stintifice medicina veterinara*, 42 (2):342-346.
13. Sathyamoorthy, O. R. and Ramesh, G. (2006). Gross anatomical studies on the sternum of the ostrich (*Struthio camelus*). *Indian Journal Animal Health*, 45 (1):83-86.
14. Sathyamoorthy, O. R., Thirumurugan, R., Senthilkumar, K. and Jayathangaraj, M. G. (2012). Gross anatomical studies on the sternum and clavicle of spot-billed pelican (*Pelicanus philippensis*). *Tamilnadu Journal Veterinary & Animal Sciences*, 8 (3):166-170.
15. Sathyamoorthy, O. R., Churchil, R. R. and Karunakaran, N. (2019). Gross anatomical studies on the sternum of blue and yellow macaw (*Ara ararauna*). *Journal of Entomology and Zoology studies*, 7 (4): 970-973.
16. Tomar, M. P. S., Vsish, R., Parmar, M. L., Shrivastav, A. B. and Tiwari, Y. (2011). Gross morphometrical studies of sternum of pariah kite (*Milvus migrans*). *Veterinary World*, 4: 171-172.
17. Wani, S. U. A., Pathak, S. K., John, M. A., Ahmad, K., Sheikh, F. A. and Ishaque, S. (2017). Gross morphological studies on sternum of common moorhen (*Gallinula chloropus*). *International Journal of Current Microbiology and Applied Sciences*, 6 (6): 1489-1492.
