



Original Research

Electrocardiographic and Echocardiographic Parameters in Chippiparai Dog

S. Bhargavi, T. A. Kannan*, Geetha Ramesh, D. Sumathi¹ and A. Arun Prasad²

Department of Veterinary Anatomy, Madras Veterinary College, Tamil Nadu Veterinary and Animal Sciences University, Chennai, Tamil Nadu, INDIA

¹Department of Veterinary Clinical Medicine

²Department of Veterinary Surgery and Radiology

*Corresponding author: kanns2000@gmail.com

Rec. Date:	Jan 25, 2019 11:33
Accept Date:	Feb 25, 2019 11:53
DOI	10.5455/ijlr.20190125113327

Abstract

Recently, electrocardiographic and echocardiographic parameters have been recorded to assess the structural and functional status of heart among various breeds of dogs. The study was carried out in 28 clinically healthy Chippiparai dogs, an indigenous breed of Tamil Nadu. Animals were grouped into young (up to 6 months age; n=14) and adult (above 6 months age; n=14). Electrocardiography was performed using Lead II of standard bipolar limb lead system. Two-dimensional echocardiographic images were also recorded. The results were analyzed statistically. Echocardiographic study revealed no significant difference among various ECG parameters between the groups. On 2D echocardiography, significant difference was observed in LADd, LADs, AO, AOA, LAD/AO and RVD between the age groups studied. Results provided the normal reference values of various electrocardiographic and 2D echocardiographic parameters for Chippiparai dog to facilitate clinical examination.

Key words: Chippiparai Dogs, Electrocardiography, Echocardiography, Indigenous Breed

How to cite: Subramanian, B., Arthanari, K., Ramesh, G., Sumathi, D., & Arunprasad, A. (2019). Electrocardiographic and Echocardiographic Parameters in Chippiparai Dog. International Journal of Livestock Research, 9(4), 49-57. doi: 10.5455/ijlr.20190125113327

Introduction

India has a rich canine genetic resource, besides the vast wealth of livestock germplasm. Among the domestic animals, heart is the largest organ in the middle mediastinum, located between the walls of the mediastinal pleurae (Evans, 1993). Canine heart is reported to be an ovoid structure. Its long axis formed an angle of about 45° with the sternum. The base of the heart was formed by thin walled atria. Ventricles provided a much larger part of the heart that was also much firmer because of the greater thickness of the walls. The left ventricle formed the apex of the heart as a whole (Dyce *et al.*, 2010). The heart is situated between third to fifth intercostal space and occasionally as far caudally as the seventh. In case of deep



ched dogs, the position of heart is reported to be tall, narrow and upright, whereas in Barrel chested dogs it is almost globular (Done *et al.*, 2009). Understanding the importance of a healthy heart and advances in Veterinary cardiology, mostly in areas of diagnostic imaging, gives us an opportunity to add better understanding on cardiac diseases in small animals. Cardiac diseases during recent years have been considered as highly important health threatening problems among dogs and cats (Thrall, 2013).

In India, indigenous canine breeds like Rajapalayam, Chippiparai, Mudhol hound, Rampur hound, Caravan hound, Banjara hound and Jonangi are well known for hardy and disease resistance nature. Of these, Chippiparai and Rajapalayam are indigenous breeds of Tamil Nadu. Chippiparai is a unique medium-sized, sight hound breed seen in Southern part of Tamil Nadu. They have a conical shaped head with black nostrils and black eyes. Legs are long, moderately muscular and strong which helped them to be fast runners and eventually good hunters (Karthickeyan *et al.*, 2015). The predominant body colour of Chippiparai dog is fawn and occasionally brown or grey (Hisham *et al.*, 2015). Enormous data is available on cardiac anatomy in exotic dog breeds (Beagle (Crippa *et al.*, 1992), Greyhound (Page *et al.*, 1993), German Shepherd (Kayar *et al.*, 2006) and Labrador Retriever (Gugjoo, 2011)). But due to inflow of exotic canine breeds, the indigenous dogs have not received any attention from scientists (Karthickeyan *et al.*, 2015). Very little or no data is available on cardiac anatomy in Chippiparai dogs, hence, the present study has been designed to explore the reference values for electrocardiographic and echocardiographic parameters in both young and adult dogs of this particular breed.

Materials and Methods

Study Area

The study was carried out on 28 clinically healthy Chippiparai breeds of dogs (Fig. 1) brought to Madras Veterinary College teaching hospital with the consent from the owner. The dogs were grouped into two as young (up to 6 months; n=14) and adult (above 6 months of age; n=14).

Screening

All the animals were subjected to screening initially to ascertain that they were clinically healthy by physical examination and clinical examination. The history and signalments were noted. A thorough physical examination was carried out and vital parameters like respiration rate (per minute), heart rate (beats per minute), rectal temperature (°C) were recorded. Dogs with vital parameters within the established reference range were considered to be clinically healthy and subjected for further evaluation.



Fig. 1: Photograph of adult Chippiparai dog

Electrocardiography

Electrocardiography was carried out using RMS VESTA 301i Electrocardiograph using Lead II of standard bipolar limb lead system and subjective assessment of the Electrocardiogram (ECG) reading was done to ensure that the parameters were within the normal reference range for dogs (Tilley, 1992).

Echocardiography

Two-dimensional (2D) echocardiography was done at right and left parasternal long axis view at fourth / fifth intercostal space ventrally between the sternum and costochondral junction. From the long axis view, index marker of the transducer was directed towards head of the patient to obtain short axis view as per Thomas *et al.* (1993). Esoate MyLab 20 ultrasound machine with a cardiac probe of 6MHz was used for recording the echocardiographic studies. 2D echocardiographic images were recorded and stored for further evaluation.

Statistical Analysis

SPSS[®] 20.0 for Windows was used for statistical analysis of data. The data obtained from various electrocardiographic parameters were subjected to Mean \pm SE and independent sample test or t-test for equality of means.

Results and Discussion

Electrocardiography

The mean and standard error of various ECG parameters such as P wave amplitude (mV), R wave amplitude (mV), P wave duration (sec), PR interval (sec), QRS interval (sec) and Heart rate (beats/min) were recorded using Lead II of standard bipolar limb lead system (Fig. 2). Heart weight (g) was also calculated using QRS interval and body weight with Steel's formula ($Hw = (3.2 \times Hs) + (6.1 \times Bw) - K$). Statistical analysis was performed for comparison of two age groups (Table 1). Heart rate showed significant difference between

age groups and other parameters showed no significant difference and the values were mostly within the reference range for dogs.

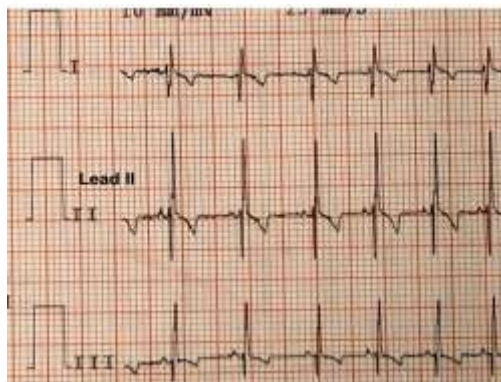


Fig. 2: ECG strip of adult Chippiparai dog showing P-QRS-T deflections

Table 1: Mean \pm SE of various ECG parameters in Chippiparai dogs

Parameters	Mean \pm SE		t value
	Young	Adult	
P amplitude (mV)	0.11 \pm 0.01	0.10 \pm 0.00	0.93 ^{NS}
R amplitude (mV)	0.80 \pm 0.19	0.87 \pm 0.15	0.28 ^{NS}
P duration (sec)	0.03 \pm 0.00	0.03 \pm 0.00	0.54 ^{NS}
PR interval (sec)	0.21 \pm 0.12	0.09 \pm 0.01	1.02 ^{NS}
QRS interval (sec)	0.04 \pm 0.00	0.03 \pm 0.00	0.81 ^{NS}
HR (beats/min)	170 \pm 12.38	136.67 \pm 6.15	2.41*
Heart Weight (g)	115.41 \pm 7.02	139.52 \pm 10.48	1.91 ^{NS}

^{NS} No significant difference between young and adult age groups ($P > 0.05$); *Significant difference between young and adult age groups ($P < 0.05$)

Statistical analysis of P wave amplitude data revealed that there was no significant difference or change in size of right atrium between young and adult age groups (Tilley *et al.*, 1990). Similar findings were reported by Pawan Kumar *et al.* (2016) in Doberman, Pomeranian and Rottweiler. Comparatively higher P wave amplitudes were recorded in other hound group of dogs such as Beagles (Hanton and Rabemampianina, 2006) and Whippets (Bavegems *et al.*, 2009). The variation in P wave amplitude might have been caused by stress during electrocardiographic examination, as the animals were not used to experimental conditions. R wave amplitude is a good indicator of ventricular compliance and contractility, whose value was in agreement with standard reference values in dogs (Tilley, 1992). A similar report was observed in Rottweiler (Pawan Kumar *et al.*, 2016). Whereas, higher R wave amplitudes were recorded in German Shepherd (Rezakhani *et al.*, 1990), Golden Retriever (Sato *et al.*, 2000) and Labrador (Gugjoo, 2011) dogs. Mean P wave duration was also within the normal reference range of 0.04 sec (Tilley, 1992). A similar

observation was recorded in Whippets (Bavegems *et al.*, 2009) which is also a deep chested, sight hound breed similar to Chippiparai.

PR interval represents the time required for an impulse to travel from SA node to the ventricle. Prolonged interval indicates first degree atrioventricular block. In Chippiparai, PR interval was higher in young than in adult age groups. According to Geis *et al.* (1975), newborn or young animals have a lower level of vagal tone as the myocardial sympathetic nervous system is not completed at birth and autonomic nervous system's response is less in young when compared to adults. QRS complex denotes ventricular depolarization (Tilley, 1992). A similar mean \pm SE value of QRS interval was recorded in Mastin Espanol dogs by Bernal *et al.* (1995) and in Retrievers by Sato *et al.* (2000) whereas, a higher mean \pm SE (0.052 ± 0.0) was recorded in Mongrel dogs (Pawan Kumar *et al.*, 2016). Significant difference was observed in heart rate between young and adult age groups which might be due to increase in body weight as age advanced which is similar to the observation made by Bernal *et al.* (1995). No significant difference observed between the age groups indicated that the heart weight proportionately increased as age advanced.

Echocardiographic Parameters – 2D

Mean \pm SE of all the 2D echocardiographic parameters *viz.*, left ventricular diameter during diastole and systole (LVD) (cm), left ventricular posterior wall thickness during systole and diastole (LVPW) (mm), interventricular septal thickness during systole and diastole (IVS) (mm), left atrial diameter (LAD) (cm), aortic root diameter (AO) (cm), aortic area (AOA) (cm²), left atrial posterior wall thickness (LAPW) (mm), LAD/AO ratio, right ventricular diameter (RVD) (cm) and right ventricular posterior wall thickness (RVPW) (mm) measured were tabulated (Fig. 3; Table 2). T-test for equality of means was performed to detect the significant difference between the two age groups studied (young and adult). High significant difference ($P < 0.01$) was observed in LADs, AO and RVD in Chippiparai dogs between the age groups. LADd, AOA and LAD/AO also showed significant difference ($P < 0.05$) between young and adult groups whereas, no significant difference was observed between the age groups for rest of the parameters measured.

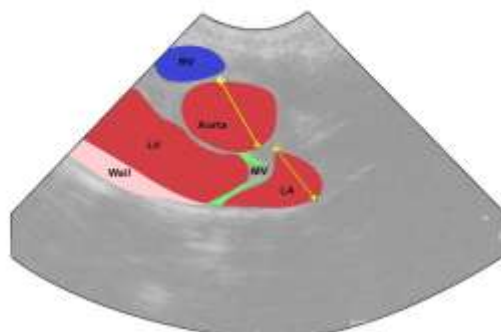
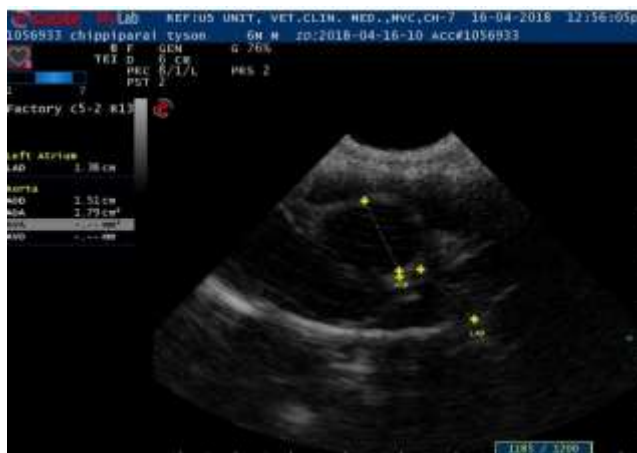

Fig. 3: 2D-Echocardiographic image and line diagram– Right long axis view of Chippiparai dog showing left atrium (LA), left ventricle (LV), mitral valve (MV), right ventricle (RV) and left ventricular posterior wall (Wall)

Table 2: Mean \pm SE of various 2D echocardiographic parameters in Chippiparai dogs

Parameters	Mean \pm SE		t value
	Young	Adult	
LVDd (cm)	2.17 \pm 0.29	1.84 \pm 0.19	0.95 ^{NS}
LVDs (cm)	2.00 \pm 0.33	1.76 \pm 0.21	0.63 ^{NS}
LVPWd (mm)	7.32 \pm 0.04	7.33 \pm 0.24	0.05 ^{NS}
LVPWs(mm)	7.19 \pm 0.02	7.07 \pm 0.22	0.56 ^{NS}
IVSd (mm)	6.82 \pm 0.25	6.96 \pm 0.15	0.48 ^{NS}
IVSs (mm)	5.43 \pm 0.32	6.28 \pm 0.28	2.02 ^{NS}
LADd (cm)	1.33 \pm 0.17	1.88 \pm 0.14	2.52*
LADs(cm)	0.92 \pm 0.05	1.47 \pm 0.15	3.42**
AO (cm)	1.55 \pm 0.01	1.88 \pm 0.10	3.15**
AOA (cm ²)	1.95 \pm 0.05	2.86 \pm 0.31	2.90*
LAPWd (mm)	1.48 \pm 0.06	1.40 \pm 0.04	1.15 ^{NS}
LAPWs (mm)	1.16 \pm 0.07	1.08 \pm 0.05	0.99 ^{NS}
LAD/AO	0.86 \pm 0.04	1.00 \pm 0.05	2.54*
RVD (cm)	2.29 \pm 0.09	1.66 \pm 0.10	4.78**
RVPW (mm)	5.04 \pm 0.02	5.64 \pm 0.28	2.09 ^{NS}

^{NS}No significant difference between young and adult age groups ($P > 0.05$); *Significant difference between young and adult age groups ($P < 0.05$); **Significant difference between young and adult age groups ($P < 0.01$)

Left Ventricular Dimensions

Diastolic dimensions of left ventricle determine the presence or absence of left ventricular volume overload. This measurement reflects maximum ventricular filling when the heart is relaxed. Systolic measurements are a reflection of systolic function in the heart and should not be used to assess the presence of dilatation and it also signifies increased function (Boon, 1998). This parameter is of significant help in the direct assessment of cardiomyopathies and indirect assessment of abnormal connections between cardiac chambers and congenital defects (Saxena, 2008). LVPW_s value was greater than LVPW_d in both the age groups studied. This is in contrast to the findings of Crippa *et al.* (1992) and Jacobson *et al.* (2013). Mean values of IVS_d and IVS_s in young and adult groups showed no significance which is in line with the findings of Gooding *et al.* (1986), Lombard (1984), Sisson and Schaeffer (1991), Bayon *et al.* (1994), Kayar *et al.* (2006) and Gugjoo (2011).

Left Atrial and Aortic Parameters

Mean \pm SE for LAD_d was similar to the reports of DellaTorre *et al.* (2000) and Bavegems *et al.* (2007) in Whippets (1.88) and Italian Greyhounds (1.43) respectively. However, increased values were reported by Morrison *et al.* (1992), Bayon *et al.* (1994) and Vollmar (1999). AO value recorded was very close to the findings of Morrison *et al.* (1992) in Pembroke Welsh Corgie (1.8). The same was reflected in aortic area (cm²) which was lesser in young dogs (1.95) than in adult dogs (2.86). Larger AO diameter in adult animals might be due to increased physical activity as reported by Snoeckx *et al.* (1982) and Vanoverschelde *et al.* (1993). The mean diastolic and systolic LAPW was thicker in young dogs and the same was found to be thinner in adult dogs. Thinner LAPW in adult dogs indicates that they may be prone for atrial fibrillation (Platonov *et al.*, 2008). LAD/AO denotes severity of atrial dilation. This is reliable because cardiac chambers usually maintain a fixed relationship with one another. In Chippiparai, the left atrium to aortic root ratio was in accordance with the established range of LAD/AO ratio recorded by Bonagura and Pipers (1983).

Right Ventricular Dimensions

Right sided cardiac disease could be assessed with the help of Right ventricular dimensions. Higher values of RVD were recorded in Irish Wolfhound (2.87 ± 0.38) by Vollmar (1999)-whereas, lesser values of 1.35 were recorded in German Shepherd (Kayar *et al.*, 2006). Mean \pm SE of RVPW was lesser than the findings of Matsukubo *et al.* (1977). The present study provided the basic reference data for ECG and Echocardiography in Chippiparai dogs, the indigenous sight hound breed of Tamil Nadu.

Conclusion

As there is increase in the number of native breeds brought to Veterinary hospitals and non-availability of data on the reference values of electrocardiographic and echocardiographic parameters, results of this study will help in setting up a basic reference data in cardiac anatomy of Chippiparai dogs. These documented reference values also help in diagnosis of various cardiovascular diseases in Chippiparai dogs.

Acknowledgments

The authors acknowledges the Dean, Madras Veterinary College and the authorities of Tamil Nadu Veterinary and Animal Sciences University, Chennai for providing necessary facilities to carry out the research work.

References

1. Bavegems, V., Duchateau, L., Ham, L. V., Rick, A. and Sys, S.U. (2009). Electrocardiographic reference values in Whippets. *The Veterinary Journal*. 182(1):59-66.
2. Bavegems, V., Duchateau, L., Sys, S. U. and Rick, A. D. (2007). Echocardiographic reference values in Whippets. *Veterinary Radiology & Ultrasound*. 48(3):230-238.
3. Bayon, A., Palacio del, M. J. F., Montes, A. M. and Panizo, C. G. (1994). M-mode echocardiography study in growing Spanish mastiffs. *Journal of Small Animal Practice*. 35:473-479.
4. Bernal, L. J., Montes, A. M., Palacio del, M. J. F. and Panizo, C. G. (1995). Electrocardiographic changes in the growing Mastin espanol. *Journal of Small Animal Practice*. 36:221-228.
5. Bonagura, J. D. and Pipers, F. S. (1983). Echocardiographic features of aortic valve endocarditis in a dog, a cow and a horse. *Journal of American Veterinary Medical Association*. 182:595-599.
6. Boon, J. A. (1998). *Manual of Veterinary Echocardiography*. Baltimore, USA. Williams and Wilkins.
7. Crippa, L., Ferro, E., Melloni, E., Brambilla, P. and Cavalletti, E. (1992). Echocardiographic parameters and indices in the normal beagle dog. *Laboratory Animals*. 26: 190-195.
8. DellaTorre, P. K., Kirby, A. C., Church, D. B. and Malik, R. (2000). Echocardiographic measurements in Greyhounds, Whippets and Italian Greyhounds - Dogs with a similar conformation but different size. *Australian Veterinary Journal*. 78 (1): 49-55.
9. Done, S. H., Goody, P. C., Evans, S. A. and Stickland, N. C. (2009). *Colour Atlas of Veterinary Anatomy. Volume 3. The Dog and Cat*. Elsevier Ltd. 194-196.
10. Dyce, K. M., Sack, W. O. and Wensing, C. J. G. (2010). *Textbook of Veterinary Anatomy*. Philadelphia, Pennsylvania.
11. Evans, H. E. (1993). *Miller's anatomy of the dog*. Philadelphia. WB Saunders.
12. Geis, W. P., Tatoes, C. J., Priola, D. V. and Friedman, W. P. (1975). Factors influencing neurohumoral control of the heart in the new born dog. *American Journal of Physiology*. 228: 1685-1689.
13. Gooding, J. P., Robinson, W. F. and Mews, G. C. (1986). Echocardiographic assessment of left ventricular dimensions in clinically normal English Cocker Spaniels. *American Journal of Veterinary Research*. 47: 296-300.
14. Gugjoo, M.B. (2011). Determination of Radiographic, Electrocardiographic, Echocardiographic and Haemato-biochemical cardiac reference values in Labrador Retriever. M.V.Sc. Thesis, Deemed University, Indian Veterinary Research Institute, Izatnagar, India.
15. Hanton, G. and Rabemampianina, Y. (2006). The electrocardiogram of the Beagle dog: reference values and effect of sex, genetic strain, body position and heart rate. *Laboratory Animals*. 40 (2): 123-136.



16. Hisham, A., Karthickeyan, S. M. K., Ravimurugan, T. and Sivaselvam, S. N. (2015). Chippiparai breed of dogs in Tamil Nadu: an assessment of physical and performance characteristics. *Indian Journal of Science and Biotechnology*, 10(3):45-49.
17. Jacobson, J. H., Boon, J. A. and Bright, J. M. (2013). An echocardiographic study of healthy Border Collies with normal reference ranges for the breed. *Journal of Veterinary Cardiology*. 15: 123-130.
18. Karthickeyan, S. M. K., Ravimurugan, T., Hisham, A. and Sivaselvam, S. N. (2015). Chippiparai breed of dogs in Tamil Nadu: an assessment of physical and performance characteristics. *Indian Journal of Science and Biotechnology*, 10(3): 45-49.
19. Kayar, A., Gonul, R., Or, M. E. and Uysal, A. (2006). M-mode echocardiographic parameters and indices in the normal German shepherd dog. *Veterinary Radiology & Ultrasound*. 47 (5): 482-486.
20. Lombard, C. W. (1984). Normal values of the canine M-mode echocardiogram. *American Journal of Veterinary Research*. 45: 2015-2018.
21. Matsukubo, H., Matsuura, T., Endo, N., Asayama, J., Watanabe, T., Furukawa, K., Kunishige, H., Katsume, H. and Ijichi, H. (1977). Echocardiographic Measurement of right ventricular wall thickness. *Circulation*. 56 (2): 278.
22. Morrison, S. A., Moise, N. S., Scarlet, J., Mohammed, H. and Yeager, A. E. (1992). Effect of breed and bodyweight on echocardiographic values in four breeds of dogs of differing somatotype. *Journal of Veterinary Internal Medicine*. 6: 220-224.
23. Page, A., Edmunds, G. and Atwell, R. B. (1993). Echocardiographic values in the greyhound. *Australian Veterinary Journal*. 70: 361-364.
24. Pawan Kumar, C., Syaama Sundar, N., Praveena, G., Soma Sekhar Reddy, B. and Siva Kumar, R. V. (2016). Electrocardiographic studies in certain breeds of dogs. *Indian Journal of Canine Practice*. 8 (1): 1-4
25. Platonov, P. G., Ivanov, V., Ho, S. Y. and Mitrofanova, L. (2008). Left atrial posterior wall thickness in patients with and without atrial fibrillation: data from 293 consecutive autopsies. *Journal of Cardiovascular Electrophysiology*. 19 (7): 1540-8167.
26. Rezakhani, A., Atwell, R. B. and Webester, J. (1990). Electrocardiographic values of German Shepherd dogs. *Australian Veterinary Journal*. 67: 307-309.
27. Sato, H., Yoko, F. and Yoshito, W. (2000). Standard electrocardiographic values in normal retrievers. *Advances in Animal Cardiology*. 33(1):11-15.
28. Saxena, A. C. (2008). Studies on the measurement of reference ranges of echocardiographic indices and related cardiac parameters in Indian Spitz breed of dogs. M.V.Sc. Thesis, Deemed University, Indian Veterinary Research Institute, Izatnagar, India.
29. Sisson, D. and Schaeffer, D. (1991). Changes in linear dimensions of the heart, relative to body weight, as measured by M-mode echocardiography in growing dogs. *American Journal of Veterinary Research*. 52:1591-1596.
30. Snoeckx, L. H. E. H., Abeling, H. F. M., Lambregts, J. A. C., Schmitz, J. J. F., Verstappen, F. T. J. and Reneman, R. S. (1982). Echocardiographic dimensions in athletes in relation to their training programs. *Medicine & Science in Sports & Exercise*. 14(6):428-434.
31. Thomas, W. P., Gaber, C. E., Jacobs, G. J., Kaplan, P. M., Lombard, C. W., Moise, N. S. and Moses, B. L. (1993). Recommendations for standards in transthoracic two-dimensional echocardiography in the dog and cat. *Journal of Veterinary Internal Medicine*. 7:247-252.
32. Thrall, D.E. (2013). *Textbook of veterinary diagnostic radiology*. Saunders: Elsevier.
33. Tilley, L. P., Smith, F. W. K. and Miller, M. S. (1990). *Cardiology Pocket Reference*. Denver., 19-21.
34. Tilley, L. P. (1992). *Essentials of canine and feline electrocardiography. Interpretation and Treatment*. Philadelphia; Lea & Febiger.
35. Vanoverschelde, J. J., Essamri, B. and Vanbutsele, R. (1993). Contribution of left ventricular diastolic function to exercise capacity in normal subjects. *Journal of Applied Physiology*. 74(5):2225-2233.
36. Vollmar, A. C. (1999). Echocardiographic measurements in the Irish wolfhound: reference values for the breed. *Journal of American Animal Hospital Association*. 35:271-277.

