



Original Research

Gross and Histopathology of Coccidiosis in Small Ruminants in Tamil Nadu

A. C. Satish¹, K. Nagarajan^{1*}, C. Balachandran¹, C. Soundararajan² and R. Legadevi¹

Madras Veterinary College, Tamil Nadu Veterinary and Animal Sciences University, Chennai - 600007, Tamil Nadu, INDIA

¹Department of Veterinary Pathology

²Department of Veterinary Parasitology

*Corresponding author: nagavet@gmail.com

Rec. Date:	Jun 03, 2018 05:44
Accept Date:	Nov 16, 2018 00:27
DOI	10.5455/ijlr.20180603054413

Abstract

Coccidiosis, caused by protozoa of the genus Eimeria, is one of the major parasitic diseases characterized by subclinical contagious enteritis in domestic and wild animals. A total of 125 tissue samples (abomasum, small intestine and large intestine) of sheep and goat were collected from slaughter houses in Chennai, Kanchipuram and Tiruvallur districts and samples from necropsied small ruminants at Department of Veterinary Pathology, Madras Veterinary College, Chennai, Tamil Nadu, India. The overall prevalence of coccidiosis -as single infection was 28.57% (10/35). Grossly, the ileum and jejunum infected with coccidia showed oedema, congestion of serosa and mucosa. In few cases, the ileum showed a single white round raised spot. On histopathological examination, infected tissues showed different developmental stages like early, young and mature first generation schizonts with stage of blastophore formation, early stage of compartmentalization, advanced stage of compartmentalization, early and mature second generation schizonts with stage of merozoite formation, macromeronts, micromeronts, mature meronts, microgametocytes, macrogametocytes, microgamonts, macrogamonts and mature oocysts in the intestinal mucosa mainly in the epithelial crypts.

Key words: Coccidiosis, Developmental Stages, Gross, Goat, Histopathology, Sheep

How to cite: Satish, A., Nagarajan, K., Balachandran, C., Soundararajan, C., & Legadevi, R. (2019). Gross and Histopathology of Coccidiosis in Small Ruminants in Tamil Nadu. International Journal of Livestock Research, 9(2), 225-235. doi: 10.5455/ijlr.20180603054413

Introduction

Goat is regarded as one of the most resourceful and efficient ruminant all over the world (Mussman, 1982). Caprine coccidiosis is caused by monoxenic apicomplexan parasites of the genus *Eimeria*, which parasitize different parts of the small and large intestine of goats (Chartier and Paraud, 2012), leads to economic losses due to high mortality and morbidity, poor growth and treatment costs (Dai *et al.*, 2006). Among the 17



species of *Eimeria* described in goats, *E. christenseni*, *E. arloingi*, *E. caprina*, and *E. ninakohlyakimovae* are considered to be highly pathogenic. *Eimeria ovinoidalis* in sheep are the most pathogenic species (Ruiz *et al.*, 2006). Severe non-haemorrhagic typhlocolitis is characteristics of infection by *E. ninakohlyakimovae* with mortality rates in goat kids are up to 30% (Koudela and Bokova, 1998). The present paper deals with gross and histopathology of coccidiosis in small ruminants in Tamil Nadu, India.

Materials and Methods

A total of 120 tissue samples (75 abomasum, 25 small intestines and 20 large intestines) in Chennai, Kanchipuram and Tiruvallur districts, respectively were collected from each individual animal after slaughtering. A total of five tissue samples (abomasum, small intestine and large intestine) from each individual animal during the time of necropsy were collected. Small intestine like duodenum, jejunum and ileum were collected and large intestine like caecum (whole), colon and rectum were collected in 10% formal saline and were kept for 24 hours for proper fixation. The fixed samples were dehydrated in ascending grades of alcohol, hardened, cleared, embedded in paraffin and sectioned at 5 µm thicknesses for light microscopy and stained with haematoxylin and eosin (H&E) following standard histopathological procedures (Stevens and Wilson, 1996). Special stain such as PAS was used wherever necessary.

Results and Discussion

Prevalence

Out of 125 samples, 35 showed unsporulated oocysts in the dung sample collected from the intestinal loop with overall prevalence of 28.00%. Among the 35 samples, 28.57% (10/35) showed as single infection which was similar to that of Buragohain *et al.* (2013) and Arunkumar and Nagarajan, (2013) reported 26.75 and 27.53% of coccidiosis in kids in Assam and Thiruvallur district of Tamil Nadu respectively. Senthilvel *et al.* (2004) reported highest 63.43% of coccidiosis in goat with in Tamil Nadu. Goats affected with coccidiosis showed mucous mixed watery diarrhea (Plate 1a).

Gross Pathology

Grossly, the ileum and jejunum infected with coccidia showed oedema, congestion of serosa and mucosa. In few cases, the ileum showed a single white round raised spot (Plate 1b, c & d).

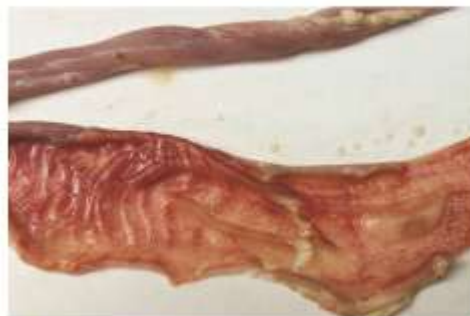Histopathology

On histopathological examination, abomasum of goat infected with coccidiosis showed mature first generation schizonts in more advanced stage of merozoite formation with mild haemorrhage, mononuclear cell (MNC) infiltration and mild destruction of crypts (Plate 1e & f).

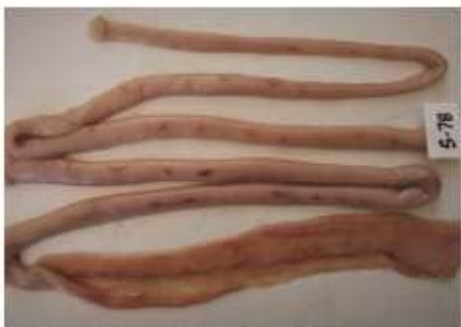Plate-1



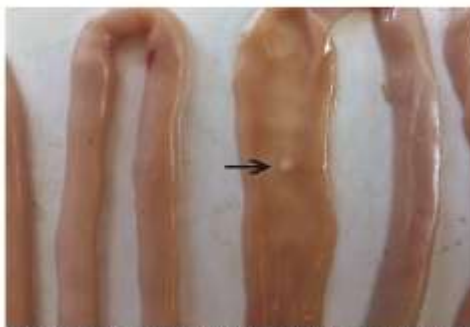a. Goat-Coccidiosis- Animal showing mucus mixed watery diarrhoea, soiled on tail and hind portion



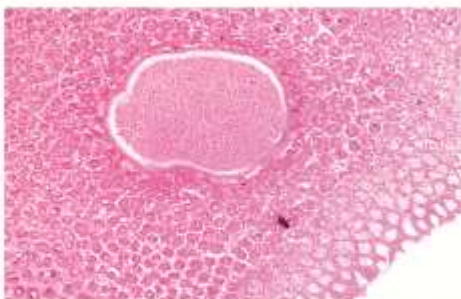
b. Goat-Ileum- Coccidiosis-Severe mucosal congestion



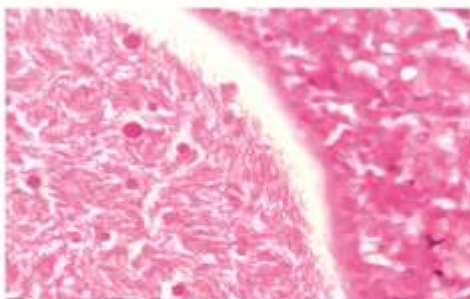
c. Goat- Jejunum-Coccidiosis-Severe serosal and mucosal congestion



d. Sheep-Ileum- Coccidiosis-Single white round raised spot (Arrow)



e. Goat-Abomasum-HP-Coccidiosis-First generation schizont in more advanced stage of merozoite formation H&E, 100x



f. Goat-Abomasum-HP-Coccidiosis-Mature first generation schizont showing thousands of tiny banana /spindle shaped merozoites H&E, 400x

Plate 1: Gross and histopathology due to coccidiosis in sheep and goats

Jejunum of sheep showed eosinophilic circular to irregular structures of developmental stages of *Eimeria* spp. occupying a portion of intestine completely parasitising mucosal epithelial cell layers (Plate 2a) which is similar to that of Sayin *et al.* (1980). It also showed the first generation macromeronts without vacuoles in lacteal of villus and distending with severe necrosis, fusion and stunting of villi (Plate 2b). Severe

lymphocytolysis in Peyer's patches with decreased lymphocytes in the medulla and cortex (Plate 2c) with necrosis of villi and severe infiltration of MNCs were noticed in jejunum (Plate 2d).

Plate-2

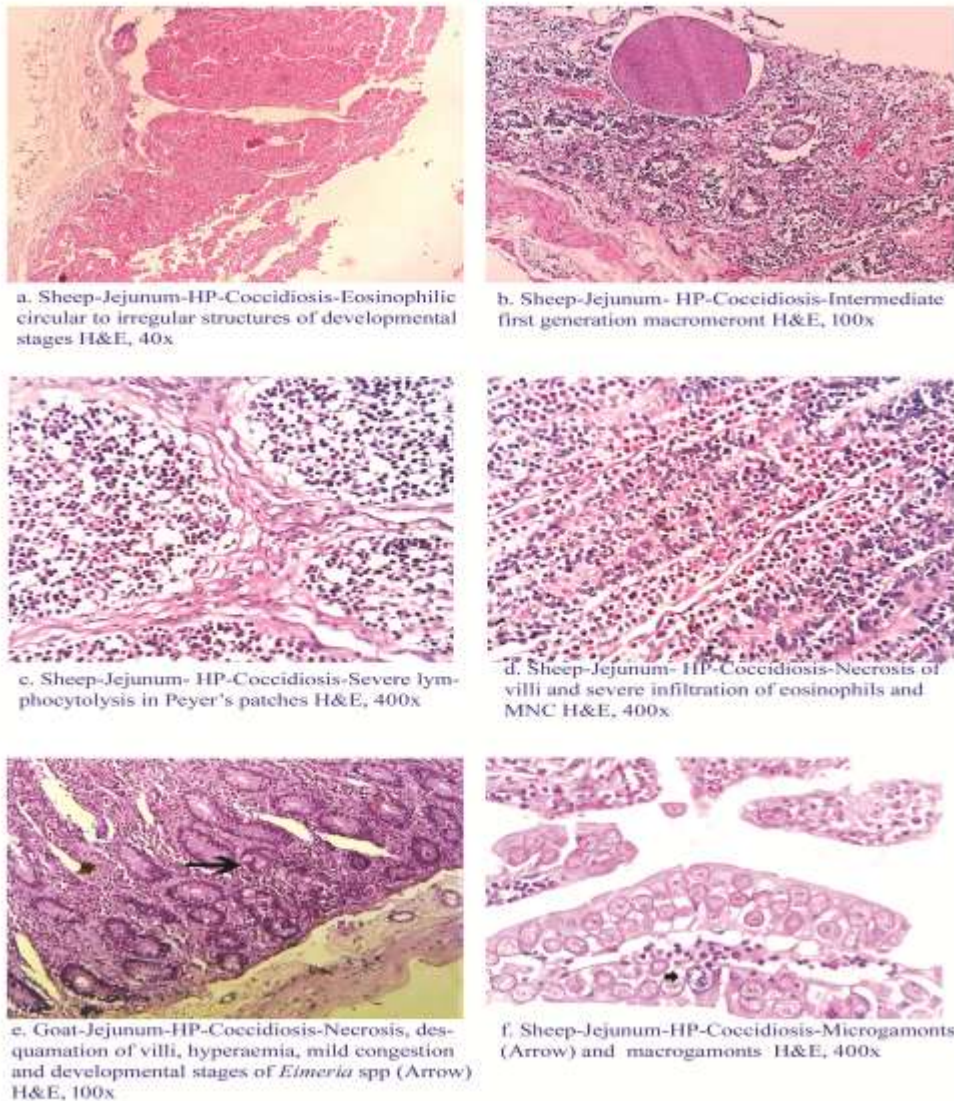


Plate 2: Histopathological lesion in jejunum due to coccidiosis in sheep

Developmental stages like macrogamonts and microgamonts infecting the segment of intestine (Plate 2e) were seen in another jejunum of sheep. Eosinophilic nuclei in the macrogamonts and basophilic nuclei in the microgamonts were arranged in periphery with infiltration of eosinophils, lymphocytes and a few plasma cells in the infected area (Plate 2f). These findings were in accordance to that of Sayin *et al.* (1980) and Koudela and Bokova (1998) who described local hypertrophy, hyperplasia of intestinal villi, villus

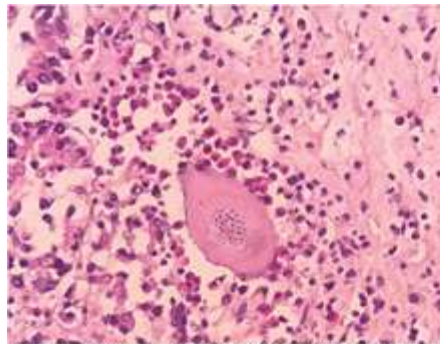


blunting, inflammatory cell infiltration in the lamina propria with numerous developmental stages of the parasites in enterocytes and lacteals of intestinal villi.

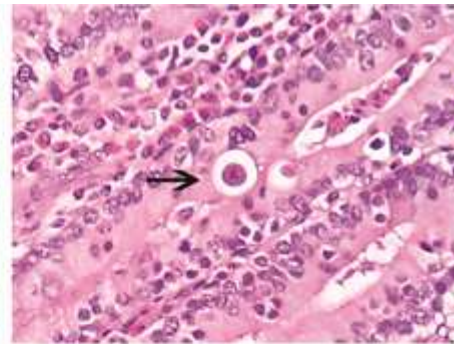
Jejunum of goat infected with coccidiosis showed early first generation schizonts with several nuclei (Plate 3a), young first generation schizonts (Plate 3b) and ileum of goat showed intermediate first generation schizonts in the early stage of blastophore formation (Plate 3c) and in the early stage of compartmentalization characterized by eosinophilic schizonts with thin eosinophilic irregular border severely infiltrated by MNC (Plate 3d). Jejunum of goat infected by coccidiosis showed intermediate first generation schizonts in the more advanced stage of compartmentalization characterized by multiple round to irregular eosinophilic compartments with peripherally arranged basophilic nuclei with congestion, fusion and severe necrosis of intestinal villi (Plate 3e). These findings were in accordance to that of Sayin *et al.* (1980) and Taylor *et al.* (2003).

Developmental stages like intermediate microgametocyte with randomly distributed nuclei, more advanced intermediate microgametocytes with peripheral layer of nuclei and residual body with infiltration of lymphocytes and eosinophils with necrosis (Plate 3f) were noticed. Desquamation of villi, hyperaemia in mucosa and mild congestion (Plate 4a) were also noticed. Ileum of goat showed mature microgametocytes in the stage of microgamete formation (Plate 4b). These findings are in accordance with Kheirandish *et al.* (2014).

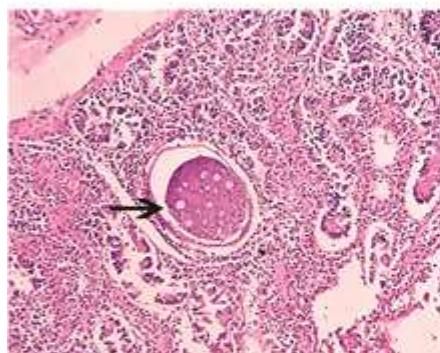




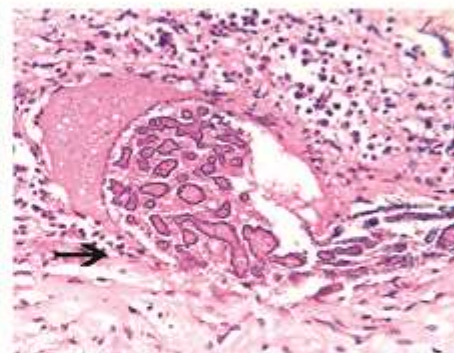
a. Goat-Jejunum-HP-Coccidiosis-Early first generation schizont with eosinophilic cell infiltration H&E, 400x



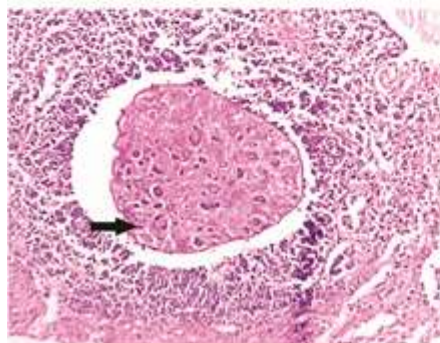
b. Goat-Jejunum-HP-Coccidiosis-Young first generation schizonts (Arrow) H&E, 400x



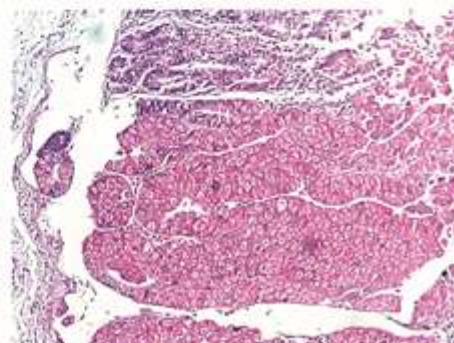
c. Goat-Ileum-HP-Coccidiosis-Intermediate first generation schizont in the early stage of blastophore formation (Arrow) surrounded by the inflammatory cells H&E, 100x



d. Goat-Jejunum-HP-Coccidiosis-Eosinophilic schizonts with thin eosinophilic irregular border severely infiltrated by MNC (Arrow) H&E, 400x



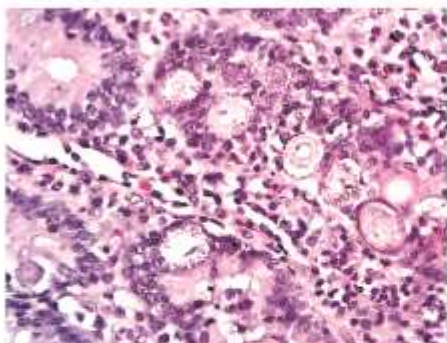
e. Goat-Jejunum-HP-Coccidiosis-Intermediate first generation schizonts in the more advanced stage of compartmentalization (Arrow). H&E, 100x



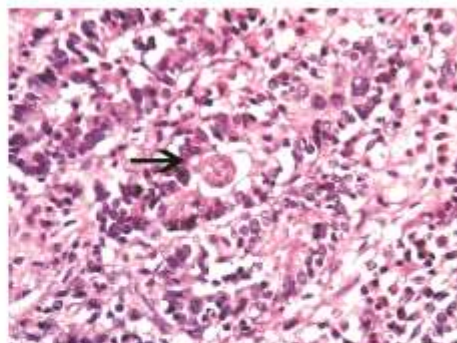
f. Goat-Ileum-HP-Coccidiosis-Developmental stages of macrogamonts and microgamonts H&E, 100x

Plate 3: Histopathology of developmental stages of *Eimeria* schizonts in the jejunum and ileum of goat

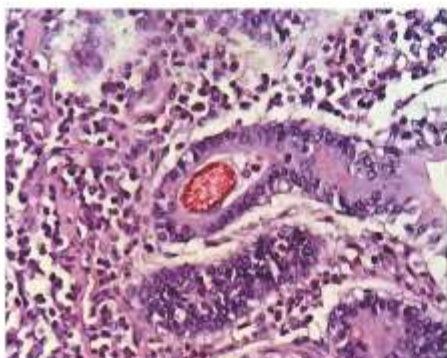
Plate-4



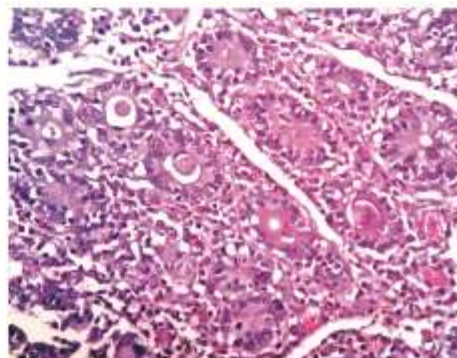
a. Goat-Ileum-HP-Coccidiosis-Advanced intermediate microgametocytes H&E, 400x



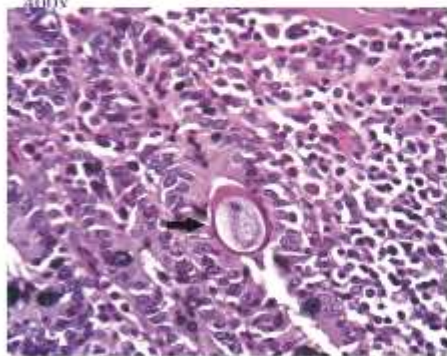
b. Goat-Ileum-HP-Coccidiosis-Mature microgametocytes in the stage of microgamete formation (Arrow) H&E, 400x



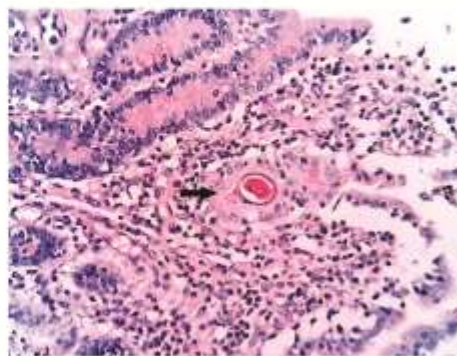
c. Sheep-Ileum-HP-Coccidiosis-Mature gamonts, characterized by eosinophilic peripheral layer of granules with infiltration of lymphocytes, plasma cells and eosinophils PAS, 400x



d. Goat-Ileum-HP-Coccidiosis-Intermediate microgametocytes (a), early gamont stage (b) and oocyst (c) PAS, 400x



e. Goat-Ileum-HP-Coccidiosis-Primitive oocyst (Arrow) H&E, 400x



f. Goat-Ileum-HP-Coccidiosis-Mature oocyst (Arrow) PAS, 100x

Plate 4: Histopathology of developmental stages of Eimeria gamonts and oocysts in the jejunum and ileum of sheep and goat

Ileum of sheep showed mature gamonts, characterized by eosinophilic peripheral layer of granules with infiltration of lymphocytes, plasma cells and eosinophils (Plate 4c). Ileum of goat showed an early gamont stages, intermediate microgametocytes and oocysts in the lumen of crypts with infiltration of eosinophils, plasma cells and lymphocytes. The early gamont stages were characterized by a prominent nucleolus near the centre of the large nucleus and granular cytoplasm (Plate 4d). A primitive oocysts were found in the crypt lumen with eosinophilic wall (Plate 4e) and mature oocysts were found with thick basophilic membrane within the crypt's lumen with necrosis, desquamation of villi and inflammatory cells infiltration (Plate 4f). These were in agreement to that of Gazyagci *et al.* (2015).

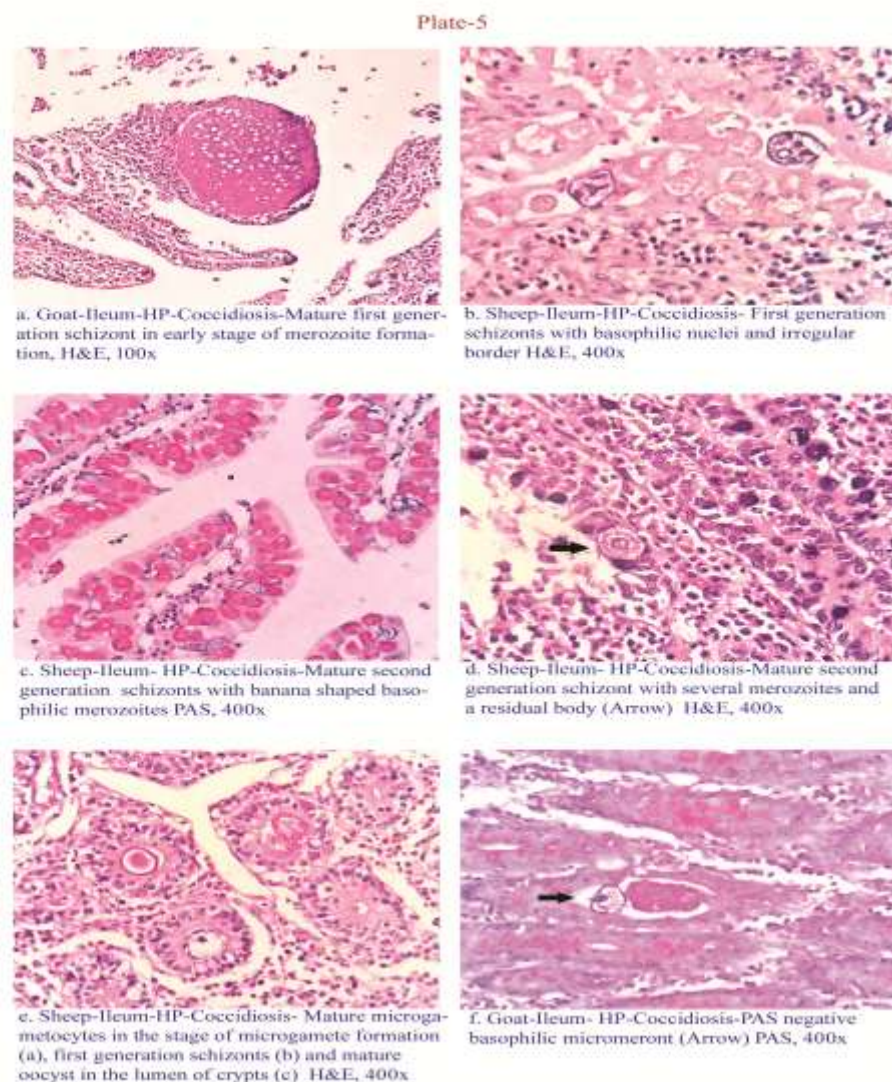


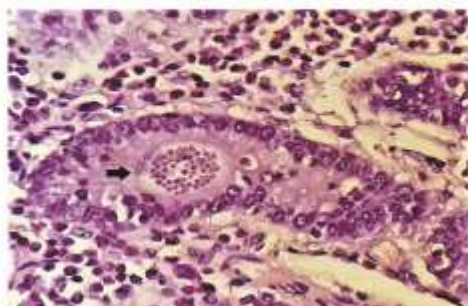
Plate 5: Histopathology of developmental stages of *Eimeria* schizonts in the ileum of sheep and goat

Ileum of goat showed mature first generation schizonts in early stage of merozoite formation, characterized by eosinophilic mature schizonts with moderate destruction of crypts with necrosis, desquamation of villi and severe infiltration of MNC (Plate 5a). Ileum of sheep showed many first generation schizonts and mature gamonts invaded the gland epithelium completely. The first generation schizonts were characterized by basophilic nuclei with irregular border (Plate 5b). Ileum of sheep showed mature second generation schizonts with several banana shaped basophilic merozoites with or without residual bodies (Plate 5c & d). Mature microgametocytes in the stage of microgamete formation, first generation schizonts and mature oocyst in the lumen of crypts with infiltration of eosinophils, plasma cells and lymphocytes were seen. The mature microgametocyte was characterized by basophilic peripheral layer of nuclei and residual body (Plate 5e). These were in accordance to that of Sayin *et al.* (1980).

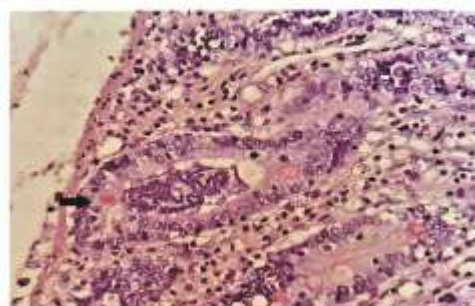
PAS on Histopathological Section of Ileum

Ileum of goat showed PAS negative basophilic micromeront in the duct of crypt with moderate number of PAS positive goblet cells (Plate 5f), intermediate microgametocytes with randomly distributed nuclei in the crypt's lumen with infiltration of lymphocytes and eosinophils (Plate 6a), more advanced intermediate microgametocytes with peripheral layer of nuclei and residual body in the crypt's duct with a few PAS positive mucin producing goblet cells and inflammatory cells infiltration (Plate 6b) and mature microgametocyte in the crypt's duct with randomly dispersed basophilic nuclei without residual body (Plate 6c). Similar findings were also observed by Khillare and Narladkar (2013). Ileum of goat showed PAS positive eosinophilic macrogamonts and PAS negative basophilic microgamonts infecting the intestinal villi with severe infiltration of lymphocytes and eosinophils into the ducts of crypts (Plate 6d). Macrogamete and mature gamont at the base of crypt characterized by peripheral layer of granules with MNC infiltration. The mature macrogametes in the lumen of crypts, characterized by hundreds of basophilic nuclei with infiltration of inflammatory cells like eosinophils and lymphocytes in between the glands which is similar to that of Khillare and Narladkar (2013). Colon of sheep infected with coccidiosis showed high PAS positive crypts with more number of mucin secreting goblet cells with infiltration of eosinophils and lymphocytes (Plate 6e). Jejunum of sheep infected with coccidiosis showed moderately PAS positive crypts with necrosis of villi and desquamation (Plate 6f). It also showed severe lymphocytolysis in Peyer's patches with decreased lymphocytes in the medulla and partially in cortex with necrosis of villi and severe infiltration of MNC. These were in accordance to that of Khillare and Narladkar (2013).

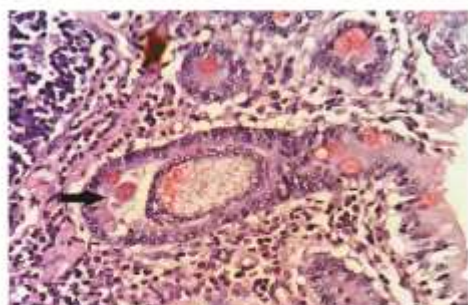
Plate-6



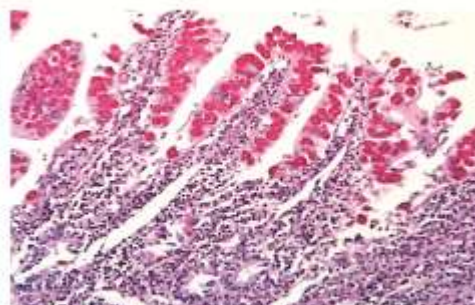
a. Goat-Ileum- HP-Coccidiosis-Intermediate microgametocyte (Arrow) PAS, 400x



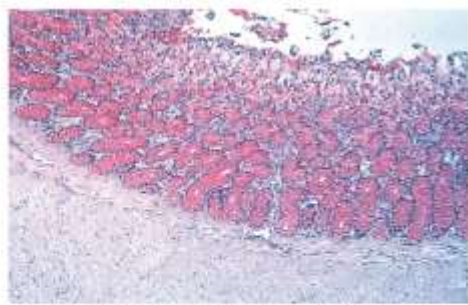
b. Goat-Ileum- HP-Coccidiosis-More advanced intermediate microgametocytes (Arrow) PAS, 400x



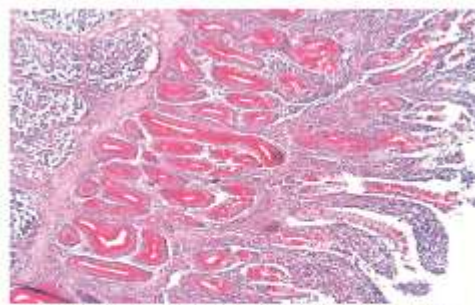
c. Goat-Ileum- HP-Coccidiosis-Mature microgametocyte (Arrow) PAS, 400x



d. Goat-Jejunum-HP-Coccidiosis-Microgamonts and macrogamonts with inflammatory cell infiltration PAS, 100x



e. Sheep-Colon- HP-Coccidiosis-PAS positive goblet cells PAS, 40x



f. Sheep-Jejunum-HP-Coccidiosis-Moderately PAS positive crypts with necrosis of villi. PAS, 100x

Plate 6: Histopathology of coccidiosis in jejunum, ileum and colon of sheep and goat (PAS stain)

Conclusion

The overall prevalence of coccidiosis -as single infection in Tamil Nadu was 28.57%. Grossly, the ileum and jejunum infected with coccidia showed oedema, congestion of serosa and mucosa. On histopathological examination, infected tissues showed different developmental stages of schizonts, merozoites, meronts, gametocytes, gamonts and oocysts in the intestinal mucosa.



Acknowledgements

First author is thankful to Indian Council of Agricultural Research (ICAR) for funding to carry out this study.

References

1. Arunkumar S and Nagarajan K. 2013. Prevalence of caprine coccidiosis in Thiruvallur district of Tamil Nadu. *International Journal of Food, Agriculture and Veterinary Sciences*. 3: 158-160.
2. Buragohain B, Phukan A, Dutta TC, Barua CC and Phukan SC. 2013. Prevalence of coccidiosis in kids in and around Guwahati. *Journal of Veterinary Parasitology*. 27: 25-28.
3. Chartier C and Paraud C. 2012. Coccidiosis due to *Eimeria* in sheep and goats, a review. *Small Ruminant Research*. 103: 84-92.
4. Dai Y, Liu X, Liu M and Tao J. 2006. Pathogenic effects of coccidium *Eimeria ninakohlyakimovae* in goats. *Veterinary Research Communication*. 30: 149-160.
5. Gazyagci AN, Antepioglu T, Canpolat S and Atmaca HT. 2015. Coccidiosis due to *Eimeria arloingi* infection in a Saanen Goat kid. *Research Journal of Veterinary Practice*. 3: 29-32.
6. Kheirandish R, Saeid R, Nourollahi-Fard and Yadegari Z. 2014. Prevalence and pathology of coccidiosis in goats in southeastern Iran. *Journal of Parasitic Diseases*. 38: 27-31.
7. Khillare BS and Narladkar BW. 2013. Species of *Eimeria* causing coccidiosis in caprines of Marathwada region of Maharashtra state. *Journal of Veterinary Parasitology*. 27: 117-122.
8. Koudela B and Bokova A. 1998. Coccidiosis in goats in the Czech Republic. *Veterinary Parasitology*. 76: 261-267.
9. Mussman HC. 1982. The animal as food resource for man with special reference to the role of animal disease, *Proc. Third Int. Conf. on Goat Production and Disease, Tucson, AZ, Dairy Goat Journal, Scottsdale, AZ*, pp. 9-14.
10. Ruiz A, Gonzalez JF, Rodriguez E, Martin S, Hernandez YI, Almeida R and Molina JM. 2006. Influence of climatic and management factors on *Eimeria* infections in goats from semi-arid zones. *Journal of Veterinary Medicine*. 53: 399-402.
11. Sayin F, Dincer S and Milli U. 1980. The life cycle and pathogenicity of *Eimeria arloingi* Marotel, 1905 Martin, 1909, in Angora kids and an attempt at its transmission to lambs. *Zentralblatt fur VeterinarmedizinReihe B*. 27: 382-397.
12. Senthilvel K, Abdul Basith S and Rajavelu G. 2004. Caprine coccidiosis in Chennai and Kancheepuram districts of Tamil Nadu. *Journal of Veterinary Parasitology*. 18: 159-161.
13. Stevens A and Wilson IG. 1996. The haematoxylin and eosin. *In: Theory and practice of histological techniques*. Eds: Bancroft, J.D. and A. Stevens. Churchill Livingstone, New York. pp. 99-112.
14. Taylor M. A., Catchpole J, Marshall J, Marshall RN and Hoeben D. 2003. Histopathological observations on the activity of diclazuril (Vecoxan) against the endogenous stages of *Eimeria crandallis* in sheep. *Veterinary Parasitology*. 116: 305-314.