



*Original Research*

## Gross Morphological and Sex Wise Morphometrical Studies on the Fourth, Fifth and Sixth Thoracic Vertebrae of Blue Bull (*Boselaphus tragocamelus*)

Srinivas Sathapathy<sup>1\*</sup>, Balwinder Singh Dhote<sup>2</sup>, Dwipjyoti Mahanta<sup>2</sup>, Tamilselvan S.<sup>2</sup>, Meena Mrigesh<sup>2</sup> and Suman Kumari Joshi<sup>3</sup>

<sup>1</sup>Department of Veterinary Anatomy and Histology CVSc. & Animal Husbandry, OUAT, Bhubaneswar-751003, Odisha, INDIA

<sup>2</sup>Department of Anatomy, CVASc., GBPUA&T, Pantnagar- 263145, Uttarakhand, INDIA

<sup>3</sup>Animal Science, KVK, Jharsuguda, OUAT, Bhubaneswar - 751003, Odisha, INDIA

\*Corresponding author: [srinivas.ouat@gmail.com](mailto:srinivas.ouat@gmail.com)

Rec. Date:	Oct 25, 2018 04:23
Accept Date:	Jan 31, 2019 16:04
DOI	<a href="https://doi.org/10.5455/ijlr.20181025042321">10.5455/ijlr.20181025042321</a>

### Abstract

The present study was carried out on the fourth, fifth and sixth thoracic vertebrae of six specimens of adult Blue bull (*Boselaphus tragocamelus*) of either sex. The first, second and third thoracic vertebrae were characterized by long supraspinous process, cylindrical, but shorter centrum. The length and breadth of supra spinous processes was observed to decrease from T<sub>4</sub> to T<sub>6</sub>. The transverse process was thick, strong that presented a rounded non-articular mammillary process and a facet ventrally. The costal facets were placed on either side at the end of the articular extremities of the centrum. The cranial articular processes were represented by oval facets on the anterior part of the arch and faced upwards, whereas the caudal ones spring from the base of the dorsal supraspinous process. The biometrical observations on different parameters of fourth, fifth and sixth thoracic vertebrae reflected significance ( $P < 0.05$ ) differences between the sexes of this species.

**Key words:** Blue Bull, Morphology, Morphometry, Thoracic Vertebrae

**How to cite:** Sathapathy, S., Dhote, B., Mahanta, D., Tamilselvan, S., Mrigesh, M., & Joshi, S. (2019). Gross Morphological and Sex Wise Morphometrical Studies on the Fourth, Fifth and Sixth Thoracic Vertebrae of Blue Bull (*Boselaphus tragocamelus*). International Journal of Livestock Research, 9(3), 207-218. doi: 10.5455/ijlr.20181025042321

### Introduction

The Blue bull (*Boselaphus tragocamelus*) is known to be one of the biggest antelopes in Asia and is widely found in both the forests and adjoining villages with enough green grass (Sathapathy *et al.*, 2017). Blue bull is considered sacred as per Hindu religion since Vedic period (1500-500 BC) and it is considered as religious. The Blue bull belongs to the family Bovidae and comes under the genus *Boselaphus* (Sathapathy *et al.*, 2018a). The German zoologist scientist Peter Simon Pallas explained this species for the first time in 1766. English zoologist scientist Philips for the first time in 1833 narrated the binomial combination of the



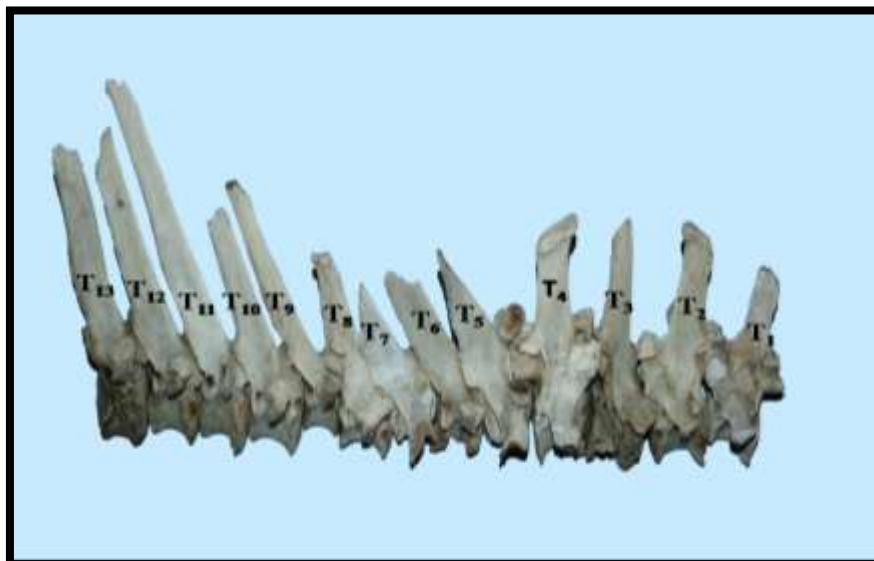Blue bull. It is quite prevalent in northern and central parts of India especially in the foothills of Himalayas, eastern part of Pakistan and southern part of Nepal, but has vanished from Bangladesh (Sathapathy *et al.*, 2018b). The adult male appears like ox and so called as Blue bull. They are usually seen in day times in the meadow pasture, timberland areas and agricultural land area. It prefers mostly plain or grassy plain and low hilly areas with shrubs, small bushes, scrub forests with scattered trees and does not usually found in dense forest areas, dense compact wood, etc. The Blue bulls are safeguarded beneath the IUCN since 2003 and also under safeguard of 'Schedule III' of the Indian Wildlife Protection Act, 1972 (Bagchi *et al.*, 2004). The Blue bull is safeguarded in various parts of India such as Gir National Park (Gujarat), Kumbhalgarh Sanctuary (Rajasthan) and Panchamarahi Biosphere Reserve, India. The massive body of the Blue bull can be attributed to the large skeleton of the antelope. Further, the skeleton comprises of large and massive bones of axial and appendicular skeleton that not only protects the viscera, but also provides shape and support to the heavy musculature of the Blue bull (Sathapathy *et al.*, 2018c). The present osteomorphological study developed a baseline data on the fourth, fifth and sixth thoracic vertebrae of adult Blue bull that would immensely help the wild life anatomists and Veterinarians in species identification and solving forensic and vetero-legal cases as no previous work has been done in this field on the Blue bull.

### Material and Method

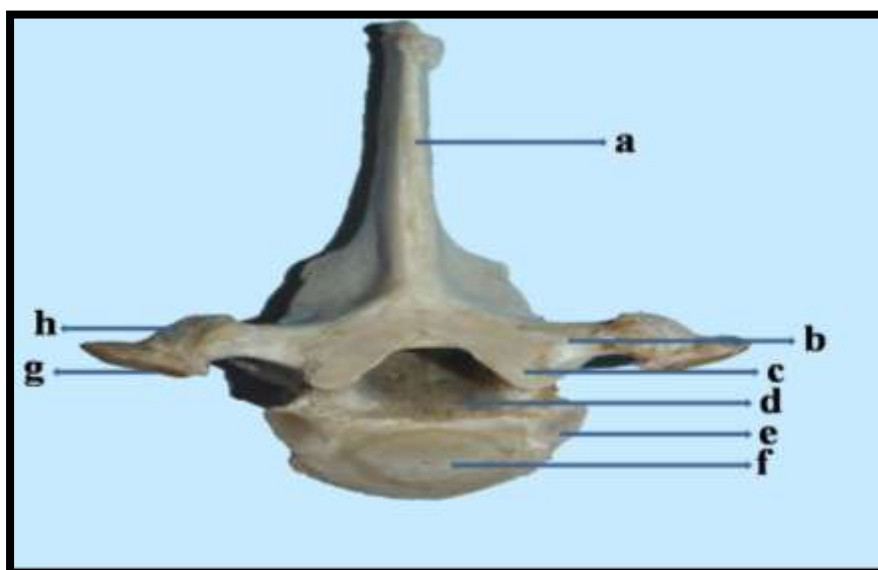
The present study was carried out on the fourth, fifth and sixth thoracic vertebrae of six specimens of adult Blue bulls (*Boselaphus tragocamelus*) of either sex. The permission for the collection of bones was acquired from the Principal Chief Conservator of Forests (PCCF), Government of Rajasthan. The bones were possessed from the Jodhpur zoo, Rajasthan getting authentic confirmation from the Principal Chief Conservator of Forests (PCCF), Government of Rajasthan. The skeletons were taken out from the burial ground that was located in the premises of the office of the Deputy Conservator of Forest Wildlife (WL), Jodhpur. Afterwards, the specimens were processed as per standard technique given by Snedecor and Cochran (1994). The gross study was conducted under the supervision of the Zoo Authority, Jodhpur, India. The different parameters of fourth, fifth and sixth thoracic vertebrae of Blue bull were measured and subjected to routine statistical analysis and independent samples t-Test with Systat Software Inc, USA and SPSS 16.0 version software.

### Result and Discussion

The thoracic vertebrae were thirteen in number in the Blue bull irrespective of sex (Fig. 1). The fourth, fifth and sixth thoracic vertebrae were characterized by long supraspinous process, cylindrical, but shorter centrum (Fig. 2). The centrum was distinctly constricted in the middle. It presented a thin-edged ventral crest. The arch presented shallow notches and was perforated by intervertebral foramina at its caudal aspect. They also presented cranial and caudal facets on their bodies.



**Fig. 1:** Lateral view of thoracic vertebrae (T<sub>1</sub> – T<sub>13</sub>) of adult female Blue bull (*Boselaphus tragocamelus*)



**Fig. 2:** Cranial view of sixth thoracic vertebra of adult female Blue bull (*Boselaphus tragocamelus*) showing a) Dorsal supraspinous process, b) Transverse process, c) Cranial articular process, d) Thoracic vertebral foramen, e) Facet on cranial surface of body for head of 9th rib, f) Cranial surface of body, g) Facet on transverse process of tubercle of rib and h) Transverse process

The length and breadth of supra spinous processes was observed to decrease from T<sub>4</sub> to T<sub>6</sub>. The transverse process was reported to be thick, strong that presented a rounded non-articular mammillary process and a facet ventrally that articulated with the facet of the tubercle of the corresponding rib. The dorsal supraspinous process presented two surfaces, two borders and a summit. The lateral surfaces were found to be convex and the borders were nearly straight. The present findings obeyed the observations made by Getty *et al.* (1930)

in ox and sheep, Breland (1943) in cat, Raghavan (1964) in ox, Miller *et al.* (1964), Kumar *et al.* (2000) in red deer, Dyce *et al.* (2006) in dog, Ozkan (2007) in mole-rats and Meena (2012) in chital, while according to Getty *et al.* (1930) in horse, there were eighteen numbers of thoracic vertebrae, according to Smuts and Bezuidenhout, (1987) there were twelve numbers of thoracic vertebrae in camel, according to Yilmaz (1998) there were fifteen numbers in porcupine, and according to Yilmaz *et al.* (2000) fourteen numbers thoracic vertebrae were present in otters. The costal facets were placed on either side at the end of the articular extremities of the centrum. Each articular facet was a demi-facet that articulated with the half the part of the head of the rib. The cranial vertebral notches were found to be shallower and smaller, but the caudal ones were deeper. The caudal arch was perforated by an additional intervertebral foramen on either side. The cranial articular processes were represented by oval facets on the anterior part of the arch and faced upwards, whereas the caudal ones spring from the base of the dorsal supraspinous process.

### Biometrical Observation

The biometrical observations revealed characteristic differences between the sexes of the Blue bull.

### Fourth Thoracic Vertebra

The biometrical studies revealed that the average weight was found to be  $127.27 \pm 1.34$  gm in adult Blue bull. Further, it was measured to be  $124.77 \pm 1.11$  gm in females that was significantly lesser ( $P < 0.05$ ) than that of males, where it was found to be  $129.77 \pm 1.24$  gm. The average length of the body was found to be  $3.38 \pm 0.10$  cm in adult Blue bull. Further, it was measured to be  $3.20 \pm 0.12$  cm in females that was significantly lesser ( $P < 0.05$ ) than that of males, where it was found to be  $3.57 \pm 0.03$  cm. Similarly, the average width of the body at the middle was found to be  $2.85 \pm 0.02$  cm in adult Blue bull. Further, it was measured to be  $2.82 \pm 0.01$  cm in females that was significantly lesser ( $P < 0.05$ ) than that of males, where it was found to be  $2.89 \pm 0.02$  cm. Pandey *et al.* (2016) in tiger (*Panthera tigris*) reported that the average widths of the body of T<sub>4</sub> at the anterior, middle and posterior aspects were  $3.00 \pm 0.07$  cm,  $2.34 \pm 0.10$  cm and  $4.10 \pm 0.03$  cm respectively.

The average height of the body was found to be  $2.84 \pm 0.02$  cm in adult Blue bull. Further, it was measured to be  $2.80 \pm 0.02$  cm in females that was significantly lesser ( $P < 0.05$ ) than that of males, where it was found to be  $2.89 \pm 0.02$  cm. The average vertical diameter of vertebral canal was found to be  $1.67 \pm 0.02$  cm in adult Blue bull. Further, it was measured to be  $1.63 \pm 0.01$  cm in females that was significantly lesser ( $P < 0.05$ ) than that of males, where it was found to be  $1.70 \pm 0.02$  cm. Similarly, the average transverse diameter of vertebral canal found to be  $1.65 \pm 0.02$  cm in adult Blue bull. Further, it was measured to be  $1.61 \pm 0.01$  cm in females that was significantly lesser ( $P < 0.05$ ) than that of males, where it was found to be  $1.69 \pm 0.02$  cm. The average width of dorsal supraspinous process at the summit was

found to be  $2.41 \pm 0.01$  cm in adult Blue bull. Further, it was measured to be  $2.39 \pm 0.01$  cm and  $2.43 \pm 0.02$  cm in females and males respectively. Similarly, the average width of dorsal supraspinous process at the middle was found to be  $2.60 \pm 0.02$  cm in adult Blue bull. Further, it was measured to be  $2.56 \pm 0.02$  cm and  $2.63 \pm 0.03$  cm in females and males respectively. The average width of dorsal supraspinous process at the base was found to be  $2.89 \pm 0.02$  cm in adult Blue bull. Further, it was measured to be  $2.86 \pm 0.02$  cm in females that was significantly lesser ( $P < 0.05$ ) than that of males, where it was found to be  $2.93 \pm 0.01$  cm.

The average height of the dorsal supraspinous process was found to be  $12.17 \pm 0.09$  cm in adult Blue bull. Further, it was measured to be  $12.03 \pm 0.09$  cm and  $12.30 \pm 0.12$  cm in females and males respectively. Kumar *et al.* (2000) and Meena *et al.* (2012) recorded the height of T<sub>4</sub> in red deer and chital to be  $10.39 \pm 0.269$  and  $14.28 \pm 0.09$  cm (maximum) respectively, but in blackbuck it was found to be  $9.84 \pm 0.028$  cm (Choudhary *et al.*, 2015b). The average length of transverse process was found to be  $1.54 \pm 0.03$  cm in adult Blue bull. Further, it was measured to be  $1.51 \pm 0.05$  cm and  $1.57 \pm 0.05$  cm in females and males respectively. The average diameter of intervertebral foramen was found to be  $0.72 \pm 0.02$  cm in adult Blue bull. Further, it was measured to be  $0.69 \pm 0.01$  cm in females that was significantly lesser ( $P < 0.05$ ) than that of males, where it was found to be  $0.76 \pm 0.02$  cm. The average length of cranial articular facet was found to be  $2.78 \pm 0.09$  cm in adult Blue bull. Further, it was measured to be  $2.74 \pm 0.13$  cm and  $2.81 \pm 0.13$  cm in females and males respectively. Similarly, the average width of cranial articular facet was found to be  $0.86 \pm 0.04$  cm in adult Blue bull. Further, it was measured to be  $0.83 \pm 0.05$  cm and  $0.89 \pm 0.05$  cm in females and males respectively. The average length of caudal articular facet was found to be  $2.81 \pm 0.01$  cm in adult Blue bull. Further, it was measured to be  $2.79 \pm 0.01$  cm in females that was significantly lesser ( $P < 0.05$ ) than that of males, where it was found to be  $2.84 \pm 0.01$  cm. The average width of caudal articular facet was found to be  $0.88 \pm 0.04$  cm in adult Blue bull. Further, it was measured to be  $0.84 \pm 0.06$  cm and  $0.92 \pm 0.06$  cm in females and males respectively.

The average distance between two cranial articular facets was found to be  $1.23 \pm 0.02$  cm in adult Blue bull. Further, it was measured to be  $1.21 \pm 0.01$  cm and  $1.26 \pm 0.04$  cm in females and males respectively. The average distance between two caudal articular facets was found to be  $0.86 \pm 0.02$  cm in adult Blue bull. Further, it was measured to be  $0.83 \pm 0.01$  cm in females that was significantly lesser ( $P < 0.05$ ) than that of males, where it was found to be  $0.90 \pm 0.01$  cm. The average distance between two cranial costal facets was found to be  $1.90 \pm 0.02$  cm in adult Blue bull. Further, it was measured to be  $1.86 \pm 0.01$  cm and  $1.93 \pm 0.02$  cm in females and males respectively. Similarly, the average distance between two caudal costal facets was found to be  $1.83 \pm 0.02$  cm in adult Blue bull. Further, it was measured to be  $1.80 \pm 0.02$  cm and  $1.86 \pm 0.02$  cm in females and males respectively. The average diameter of tubercular facet was found to be  $1.12 \pm 0.02$  cm in adult Blue bull. Further, it was measured to be  $1.08 \pm 0.02$  cm in females that was significantly lesser

( $P < 0.05$ ) than that of males, where it was found to be  $1.16 \pm 0.02$  cm. The average distance between the tubercular facet and costal facet was found to be  $1.46 \pm 0.06$  cm in adult Blue bull. Further, it was measured to be  $1.42 \pm 0.09$  cm and  $1.49 \pm 0.09$  cm in females and males respectively (Table 1).

**Table 1:** Measurements of fourth rib of Blue bull in cm

Parameters		Range	Mean	SD	SE	Female (Mean±SE)	Male (Mean±SE)	
<b>Diameter of Head</b>		2.49-2.62	2.56	0.04	0.01	2.53*±0.01	2.59±0.01	
Diameter of tubercle	Dorso-ventral	1.63-1.79	1.72	0.04	0.01	1.69*±0.02	1.74±0.01	
	Cranio-caudal	0.99-1.11	1.04	0.04	0.01	1.02*±0.01	1.07±0.02	
Length of neck	Cranial (Minimum)	0.85-1.02	0.93	0.05	0.01	0.90*±0.01	0.97±0.01	
	Caudal (Maximum)	0.97-1.10	1.04	0.04	0.01	1.01*±0.01	1.06±0.02	
<b>Length of Shaft</b>		33.2-34.1	33.55	0.28	0.08	33.43±0.08	33.67±0.13	
Width of shaft	Proximal	0.73-0.90	0.81	0.05	0.01	0.78*±0.02	0.85±0.01	
	Middle	1.78-1.94	1.86	0.05	0.01	1.83*±0.02	1.89±0.01	
	Distal	2.57-2.70	2.64	0.05	0.01	2.61*±0.01	2.68±0.01	
Diameter of articular facets of head	Cranial	Cranio-caudal	0.69-0.79	0.74	0.03	0.01	0.71*±0.01	0.76±0.01
		Dorso-ventral	1.37-1.51	1.43	0.04	0.01	1.41*±0.01	1.46±0.01
	Caudal	Cranio-caudal	0.64-0.79	0.71	0.04	0.01	0.69*±0.01	0.74±0.01
		Dorso-ventral	0.96-1.10	1.02	0.04	0.01	0.99*±0.01	1.04±0.01
Diameter of vascular groove	Proximal	0.59-0.72	0.67	0.04	0.01	0.65*±0.02	0.69±0.01	
	Middle	0.39-0.52	0.45	0.04	0.01	0.42*±0.01	0.49±0.01	
	Distal	0.31-0.43	0.39	0.04	0.01	0.36*±0.01	0.41±0.01	

Values bearing superscript (\*) differ significantly in column  $P < 0.05$

### Fifth Thoracic Vertebra

The biometrical studies revealed that the average weight was found to be  $105.74 \pm 0.78$  gm in adult Blue bull. Further, it was measured to be  $104.68 \pm 0.71$  gm and  $106.80 \pm 1.18$  gm in females and males respectively. The average length of the body was found to be  $3.42 \pm 0.09$  cm in adult Blue bull. Further, it was measured to be  $3.23 \pm 0.09$  cm in females that was significantly lesser ( $P < 0.05$ ) than that of males, where it was found to be  $3.60 \pm 0.06$  cm (Table 1). Similarly, the average width of the body at the middle was found to be  $3.05 \pm 0.03$  cm in adult Blue bull. Further, it was measured to be  $2.99 \pm 0.02$  cm in females that was significantly lesser ( $P < 0.05$ ) than that of males, where it was found to be  $3.10 \pm 0.01$  cm. Pandey *et al.* (2016) in tiger (*Panthera tigris*) reported that the average widths of the body of T<sub>5</sub> at the anterior, middle and posterior aspects were  $2.76 \pm 0.06$  cm,  $2.48 \pm 0.04$  cm and  $4.16 \pm 0.04$  cm respectively.

The average height of the body was found to be  $2.84 \pm 0.02$  cm in adult Blue bull. Further, it was measured to be  $2.81 \pm 0.02$  cm and  $2.87 \pm 0.02$  cm in females and males respectively. The average vertical diameter of vertebral canal was found to be  $1.07 \pm 0.03$  cm in adult Blue bull. Further, it was measured to be  $1.04 \pm 0.04$  cm and  $1.10 \pm 0.04$  cm in females and males respectively. The average transverse diameter of vertebral canal found to be  $2.29 \pm 0.02$  cm in adult Blue bull. Further, it was measured to be  $2.25 \pm 0.02$  cm in females that was significantly lesser ( $P < 0.05$ ) than that of males, where it was found to be  $2.33 \pm 0.02$  cm. The average width of dorsal supraspinous process at the summit was found to be  $1.14 \pm 0.02$  cm in adult Blue bull. Further, it was measured to be  $1.10 \pm 0.01$  cm in females that was significantly lesser ( $P < 0.05$ ) than that of males, where it was found to be  $1.17 \pm 0.02$  cm. Similarly, the average width of dorsal supraspinous process at the middle was found to be  $2.47 \pm 0.02$  cm in adult Blue bull. Further, it was measured to be  $2.42 \pm 0.02$  cm in females that was significantly lesser ( $P < 0.05$ ) than that of males, where it was found to be  $2.51 \pm 0.02$  cm. The average width of dorsal supraspinous process at the base was found to be  $2.79 \pm 0.02$  cm in adult Blue bull. Further, it was measured to be  $2.76 \pm 0.02$  cm and  $2.81 \pm 0.01$  cm in females and males respectively. The average height of the dorsal supraspinous process was found to be  $11.37 \pm 0.12$  cm in adult Blue bull. Further, it was measured to be  $11.17 \pm 0.12$  cm and  $11.57 \pm 0.15$  cm in females and males respectively. The average length of transverse process was found to be  $1.23 \pm 0.03$  cm in adult Blue bull. Further, it was measured to be  $1.20 \pm 0.05$  cm and  $1.26 \pm 0.05$  cm in females and males respectively. The average diameter of intervertebral foramen was found to be  $0.48 \pm 0.01$  cm in adult Blue bull. Further, it was measured to be  $0.44 \pm 0.01$  cm in females that was significantly lesser ( $P < 0.05$ ) than that of males, where it was found to be  $0.51 \pm 0.01$  cm.

The average length of cranial articular process was found to be  $2.25 \pm 0.01$  cm in adult Blue bull. Further, it was measured to be  $2.22 \pm 0.01$  cm in females that was significantly lesser ( $P < 0.05$ ) than that of males, where it was found to be  $2.28 \pm 0.02$  cm. Similarly, the average width of cranial articular process was found to be  $0.85 \pm 0.01$  cm in adult Blue bull. Further, it was measured to be  $0.82 \pm 0.01$  cm in females that was significantly lesser ( $P < 0.05$ ) than that of males, where it was found to be  $0.88 \pm 0.01$  cm. The average length of caudal articular process was found to be  $2.07 \pm 0.10$  cm in adult Blue bull. Further, it was measured to be  $2.11 \pm 0.05$  cm and  $2.03 \pm 0.19$  cm in females and males respectively. The average width of caudal articular process was found to be  $1.16 \pm 0.02$  cm in adult Blue bull. Further, it was measured to be  $1.12 \pm 0.03$  cm in females that was significantly lesser ( $P < 0.05$ ) than that of males, where it was found to be  $1.20 \pm 0.02$  cm. The average distance between two cranial articular processes was found to be  $0.95 \pm 0.02$  cm in adult Blue bull. Further, it was measured to be  $0.91 \pm 0.01$  cm in females that was significantly lesser ( $P < 0.05$ ) than that of males, where it was found to be  $0.99 \pm 0.01$  cm. The average distance between two caudal articular processes was found to be  $1.42 \pm 0.02$  cm in adult Blue bull. Further, it was measured to be  $1.38 \pm 0.02$  cm and  $1.46 \pm 0.03$  cm in females and males respectively. The average distance between two cranial costal facets

was found to be 2.74±0.02 cm in adult Blue bull. Further, it was measured to be 2.70±0.01 cm in females that was significantly lesser (P<0.05) than that of males, where it was found to be 2.77±0.02 cm. The average distance between two caudal costal facets was found to be 2.58±0.02 cm in adult Blue bull. Further, it was measured to be 2.55±0.03 cm and 2.61±0.02 cm in females and males respectively. The average diameter of tubercular facet was found to be 0.81±0.03 cm in adult Blue bull. Further, it was measured to be 0.78±0.04 cm and 0.85±0.04 cm in females and males respectively. Similarly, the average distance between the tubercular facet and costal facet was found to be 1.16±0.02 cm in adult Blue bull. Further, it was measured to be 1.13±0.02 cm and 1.19±0.02 cm in females and males respectively (Table 2).

**Table 2:** Measurements of fifth rib of Blue bull in cm

Parameters		Range	Mean	SD	SE	Female (Mean±SE)	Male (Mean±SE)	
<b>Diameter of Head</b>		1.7-3.3	2.53	0.58	0.17	2.38±0.24	2.67±0.24	
Diameter of tubercle	Dorso-ventral	1.97-2.12	2.04	0.05	0.01	2.00*±0.01	2.08±0.01	
	Cranio-caudal	1.04-1.23	1.12	0.05	0.02	1.09*±0.02	1.16±0.02	
Length of neck	Cranial (Minimum)	0.38-0.49	0.44	0.04	0.01	0.42*±0.01	0.47±0.01	
	Caudal (Maximum)	0.71-0.87	0.81	0.05	0.01	0.77*±0.02	0.84±0.01	
<b>Length of Shaft</b>		37.6-38.7	38.18	0.31	0.09	37.97*±0.08	38.38±0.10	
Width of shaft	Proximal	1.06-1.23	1.14	0.05	0.02	1.10*±0.01	1.19±0.01	
	Middle	1.33-1.42	1.4	0.04	0.01	1.37*±0.01	1.42±0.01	
	Distal	2.39-2.54	2.46	0.05	0.01	2.42*±0.01	2.50±0.01	
Diameter of articular facets of head	Cranial	Cranio-caudal	0.89-1.01	0.97	0.04	0.01	0.95*±0.02	1.00±0.01
		Dorso-ventral	1.66-1.74	1.7	0.03	0.01	1.69±0.01	1.72±0.01
	Caudal	Cranio-caudal	0.93-1.06	1	0.04	0.01	0.98±0.01	1.02±0.01
		Dorso-ventral	1.39-1.54	1.45	0.05	0.01	1.42*±0.01	1.48±0.02
Diameter of vascular groove	Proximal	0.59-0.72	0.64	0.04	0.01	0.61*±0.01	0.68±0.01	
	Middle	0.66-0.75	0.71	0.03	0.01	0.69*±0.01	0.73±0.01	
	Distal	0.49-0.66	0.58	0.05	0.02	0.55*±0.02	0.61±0.02	

Values bearing superscript (\*) differ significantly in column P < 0.05

### Sixth Thoracic Vertebra

The biometrical studies revealed that the average weight was found to be 47.19±0.99 gm in adult Blue bull. Further, it was measured to be 45.73±0.62 gm and 48.64±1.54 gm in females and males respectively. The average length of the body was found to be 3.00±0.08 cm in adult Blue bull. Further, it was measured to be 2.87±0.09 cm and 3.13±0.09 cm in females and males respectively. The average width of the body at the middle was found to be 2.39±0.02 cm in adult Blue bull. Further, it was measured to be 2.36±0.01 cm in females that was significantly lesser (P<0.05) than that of males, where it was found to be 2.41±0.01 cm. Pandey *et al.* (2016) in tiger (*Panthera tigris*) reported that the average widths of the body of T<sub>6</sub> at the anterior, middle and posterior aspects were 2.60±0.07 cm, 2.38±0.12 cm and 4.26±0.13 cm respectively.

The average height of the body was found to be  $2.07 \pm 0.02$  cm in adult Blue bull. Further, it was measured to be  $2.04 \pm 0.03$  cm and  $2.10 \pm 0.03$  cm in females and males respectively. The average vertical diameter of vertebral canal was found to be  $1.04 \pm 0.02$  cm in adult Blue bull. Further, it was measured to be  $1.00 \pm 0.02$  cm and  $1.07 \pm 0.02$  cm in females and males respectively. The average transverse diameter of vertebral canal found to be  $2.02 \pm 0.03$  cm in adult Blue bull. Further, it was measured to be  $1.96 \pm 0.02$  cm in females that was significantly lesser ( $P < 0.05$ ) than that of males, where it was found to be  $2.07 \pm 0.03$  cm. The average width of dorsal supraspinous process at the summit was found to be  $1.40 \pm 0.02$  cm in adult Blue bull. Further, it was measured to be  $1.36 \pm 0.02$  cm and  $1.43 \pm 0.01$  cm in females and males respectively. Similarly, the average width of dorsal supraspinous process at the middle was found to be  $1.63 \pm 0.02$  cm in adult Blue bull. Further, it was measured to be  $1.61 \pm 0.03$  cm and  $1.64 \pm 0.02$  cm in females and males respectively. The average width of dorsal supraspinous process at the base was found to be  $1.65 \pm 0.02$  cm in adult Blue bull. Further, it was measured to be  $1.63 \pm 0.02$  cm and  $1.68 \pm 0.02$  cm in females and males respectively. Similarly, the average height of the dorsal supraspinous process was found to be  $11.20 \pm 0.09$  cm in adult Blue bull. Further, it was measured to be  $11.07 \pm 0.12$  cm and  $11.33 \pm 0.09$  cm in females and males respectively.

The average length of transverse process was found to be  $1.78 \pm 0.02$  cm in adult Blue bull. Further, it was measured to be  $1.76 \pm 0.03$  cm and  $1.81 \pm 0.03$  cm in females and males respectively. The average diameter of intervertebral foramen was found to be  $0.25 \pm 0.01$  cm in adult Blue bull. Further, it was measured to be  $0.21 \pm 0.01$  cm in females that was significantly lesser ( $P < 0.05$ ) than that of males, where it was found to be  $0.29 \pm 0.01$  cm. The average length of cranial articular process was found to be  $1.48 \pm 0.02$  cm in adult Blue bull. Further, it was measured to be  $1.45 \pm 0.02$  cm and  $1.52 \pm 0.03$  cm in females and males respectively. Similarly, the average width of cranial articular process was found to be  $0.69 \pm 0.02$  cm in adult Blue bull. Further, it was measured to be  $0.67 \pm 0.02$  cm and  $0.72 \pm 0.03$  cm in females and males respectively. The average length of caudal articular process was found to be  $1.62 \pm 0.03$  cm in adult Blue bull. Further, it was measured to be  $1.59 \pm 0.04$  cm and  $1.65 \pm 0.04$  cm in females and males respectively. Similarly, the average width of caudal articular process was found to be  $0.62 \pm 0.03$  cm in adult Blue bull. Further, it was measured to be  $0.58 \pm 0.03$  cm and  $0.66 \pm 0.04$  cm in females and males respectively.

The average distance between two cranial articular processes was found to be  $1.03 \pm 0.02$  cm in adult Blue bull. Further, it was measured to be  $1.00 \pm 0.01$  cm and  $1.06 \pm 0.03$  cm in females and males respectively. The average distance between two caudal articular processes was found to be  $0.64 \pm 0.02$  cm in adult Blue bull. Further, it was measured to be  $0.60 \pm 0.01$  cm in females that was significantly lesser ( $P < 0.05$ ) than that of males, where it was found to be  $0.68 \pm 0.02$  cm. The average distance between two cranial costal facets was found to be  $1.62 \pm 0.02$  cm in adult Blue bull. Further, it was measured to be  $1.57 \pm 0.02$  cm in females that was significantly lesser ( $P < 0.05$ ) than that of males, where it was found to be  $1.66 \pm 0.01$  cm.

The average distance between two caudal costal facets was found to be  $1.75 \pm 0.02$  cm in adult Blue bull. Further, it was measured to be  $1.73 \pm 0.02$  cm and  $1.77 \pm 0.03$  cm in females and males respectively. The average diameter of tubercular facet was found to be  $0.97 \pm 0.03$  cm in adult Blue bull. Further, it was measured to be  $0.92 \pm 0.04$  cm and  $1.01 \pm 0.04$  cm in females and males respectively. Similarly, the average distance between the tubercular facet and costal facet was found to be  $1.17 \pm 0.03$  cm in adult Blue bull. Further, it was measured to be  $1.13 \pm 0.03$  cm and  $1.22 \pm 0.04$  cm in females and males respectively (Table 3).

**Table 3:** Measurements of sixth rib of Blue bull in cm

Parameters		Range	Mean	SD	SE	Female (Mean±SE)	Male (Mean±SE)	
<b>Diameter of Head</b>		2.7-3.6	3.11	0.24	0.07	2.97*±0.07	3.25±0.09	
Diameter of tubercle	Dorso-ventral	1.60-1.74	1.66	0.05	0.01	1.64*±0.02	1.69±0.02	
	Cranio-caudal	0.97-1.15	1.05	0.05	0.02	1.01*±0.01	1.09±0.02	
Length of neck	Cranial (Minimum)	0.59-0.74	0.68	0.04	0.01	0.65*±0.02	0.70±0.01	
	Caudal (Maximum)	0.95-1.10	1.01	0.04	0.01	0.99±0.01	1.03±0.02	
<b>Length of Shaft</b>		39.8-41.2	40.69	0.38	0.11	40.60±0.08	40.78±0.21	
Width of shaft	Proximal	0.97-1.13	1.05	0.05	0.02	1.01*±0.01	1.09±0.02	
	Middle	1.76-1.89	1.82	0.04	0.01	1.80*±0.01	1.85±0.01	
	Distal	1.18-2.29	1.74	0.53	0.15	1.71±0.22	1.78±0.23	
Diameter of articular facets of head	Cranial	Cranio-caudal	0.97-1.23	1.08	0.08	0.02	1.04±0.02	1.12±0.03
		Dorso-ventral	1.19-1.35	1.27	0.04	0.01	1.25±0.02	1.30±0.02
	Caudal	Cranio-caudal	1.16-1.28	1.22	0.04	0.01	1.20±0.01	1.24±0.02
		Dorso-ventral	1.47-1.58	1.54	0.04	0.01	1.52*±0.01	1.56±0.01
Diameter of vascular groove	Proximal	0.72-0.84	0.77	0.04	0.01	0.74*±0.01	0.81±0.01	
	Middle	0.39-0.51	0.44	0.04	0.01	0.41*±0.01	0.46±0.01	
	Distal	0.40-0.53	0.46	0.04	0.01	0.43*±0.01	0.48±0.01	

Values bearing superscript (\*) differ significantly in column  $P < 0.05$

### Conclusion

The fourth, fifth and sixth thoracic vertebrae of Blue bull were characterized by long supraspinous process, thick transverse process, cranial and caudal articular facets and cylindrical, but shorter centrum. Further, the various parameters of the fourth, fifth and sixth thoracic vertebrae like average length, width and height of body, average width and height of dorsal supraspinous process, average length and width of cranial and caudal articular facets, average length of transverse process, average diameter of tubercular facet, average diameter of intervertebral foramen, average distance between cranial and caudal costal facets and articular facets, average transverse and vertical diameters of vertebral canal showed characteristic sexual variations in the Blue bull. There is no previous information on these parameters in the fourth, fifth and sixth thoracic vertebrae neither of Blue bull, nor in any other domestic animals with which comparisons could be made. We therefore believe that the data presented above would form a baseline for further work especially

comparability and compatibility are now desirable traits as efforts are geared up towards massive improvement in the livestock sector of the international economy.

### Acknowledgements

The authors are grateful to the Dean, CVASc., GBPUA&T, Pantnagar, Uttarakhand and Ministry of Environment of Forests (MoEF), New Delhi and Jodhpur Zoo, Rajasthan, India for providing facilities and support for carrying out research on the bones of Blue bull. Funding was provided by Department of Science and Technology, New Delhi and Indian Council of Agricultural research, New Delhi, India as Ph.D. grant (DST-INSPIRE Fellowship and ICAR-SRF (PGS)) to the first author.

### References

1. Bagchi S, Goyal SP and Shankar K. 2004. "Herbivore density and biomass in a semi-arid tropical dry deciduous forest of western India". *Journal of Tropical Ecology*. 20(4): 475-478.
2. Breland OP. 1943. Manual of comparative anatomy, McGraw-Hill Book Company, Inc, New York and London, pp 146-151.
3. Choudhary OP, Singh I, Singh B, Bharti SK, Mohd KI, Sathapathy S and Kumar N 2015b. Osteo-Morphological Studies on the Thoracic Vertebrae of Indian Blackbuck (*Antelope cervicapra*). *J. Vet. Anat.* 8(1): 31 – 36.
4. Dyce KM, Sack WO and Wensing CJG. 2006. Text Book of Veterinary Anatomy, Saunders Elsevier, 4th ed., pp 35 – 41.
5. Frandson BS and Spurgeon TL. 1992. Anatomy and physiology of farm animals. Lea and Febiger, Philadelphia. 5th ed. pp 64-68.
6. Getty R, Sisson S and Grossman JD. 1930. The Anatomy of the Domestic Animals. W.B. Saunders Comp., Philadelphia. 2nd ed. (Vol. 1), pp 25-27, 33-45, 125-130.
7. König HE and Liebich HG. 2005. Veterinary Anatomy of Domestic Animals, 3rd Edn, Schattauer, Stuttgart, Germany. pp 49-104, 145-160, 215-236.
8. Kumar N, Kukreti S, Ishaque M and Mulholland R. 2000. Anatomy of deer spine and its comparison to the human spine. *The Anatomical Record Part A: Discoveries in Molecular, Cellular and Evolutionary Biology*. 260 (4): 189-203.
9. Levine JM, Levine GJ, Hoffman AG, Mez J and Bratton GR. 2007. Comparative Anatomy of the Horse, Ox and Dog: The Vertebral Column and Peripheral Nerves. CE article-1, pp 279-281.
10. Meena VK. 2012. Gross studies on the bones of vertebral column in chital (*Axis axis*). Masters' thesis submitted to the Rajasthan University of Veterinary and Animal Sciences, Bikaner.
11. Miller ME, Christensen GC and Evans HE. 1964. Anatomy of the Dog. WB Saunders Company, Philadelphia, USA, pp 51- 61.
12. Ozkan ZE. 2007. Macro-anatomical investigations on the skeletons of Mole-rat (*Spalax leucodon nordmann*) III. Skeleton axiale. *Vet. Archiv*. 77: 281-289.
13. Pandey Y, Taluja JS, Vaish R, Shahi A, Pandey A. and Shrivastav AB. 2016. Morphometry of Thoracic Vertebrae in Tiger (*Panthera tigris*). *Indian Journal of Veterinary Anatomy*. 28(2): 70-73.
14. Raghavan D. 1964. Anatomy of Ox. *Indian Council of Agricultural Research*, New Delhi, pp 17-38.
15. Rajani CV and Chungath JJ. 2012. Studies on the Lumbar, Sacral and Coccygeal Vertebrae of Indian Muntjac (*Muntiacus muntjak*). *Indian Journal of Veterinary Anatomy*. 24 (2): 78-79.
16. Sathapathy S, Dhote BS, Singh I, Mahanta D and Tamil selvan S. 2017. Gross and morphometrical studies on the sacrum of blue bull (*Boselaphus tragocamelus*). *Journal of Entomology and Zoology Studies*. 5(6): 1591-1597.



17. Sathapathy S, Dhote BS, Mrigesh M, Mahanta D and Tamil Selvan S. 2018a. Gross and Morphometrical Studies on the Sternum of Blue Bull (*Boselaphus tragocamelus*). *Int. J. Curr. Microbiol. App. Sci.* 7(01): 136-145. doi: <https://doi.org/10.20546/ijcmas.2018.701.015>.
18. Sathapathy S, Dhote BS, Singh I, Mahanta D. and Mrigesh M. and Joshi, S. K. 2018b. Gross Anatomical and Sex wise Biometrical Studies on the Atlas and Axis of Blue bull (*Boselaphus tragocamelus*). *Journal of Animal Research.* 8(1): 137-147. DOI: 10.30954/2277-940X.2018.00150.22.
19. Sathapathy S, Dhote BS, Singh I, Mahanta D, Tamil selvan S and Mrigesh M. 2018c. Gross morphometrical study on the atypical (6<sup>th</sup> and 7<sup>th</sup>) cervical vertebrae of Blue bull (*Boselaphus tragocamelus*) with special reference to sexual dimorphism. *International Journal of Livestock Research.* 8(9): 192-201. DOI 10.5455/ijlr.20180207043008.
20. Smuts MS and Bezuidenhout, AJ 1987. *Anatomy of Dromedary*, Oxford Science Publications, pp 9-20.
21. Snedecor GW and Cochran WG. 1994. *Statistical Methods*. 8th edn. Iowa State University Press, Ames, Iowa, USA.
22. Yilmaz S. 1998. Macro-Anatomical investigations on the skeletons of porcupine (*Hystrix cristita*). *Anatomia Histologia Embryologia.* 27: 293-296.
23. Yilmaz S, Dinç G and Toprak B. 2000. Macro-anatomical investigations on skeletons of otter (*Lutra lutra*) III. Skeleton axiale. *Vet. Arhiv.* 70: 191-198.

